

Effect Of Shock Waves On Fallopian Tubes Adhesion: A Randomized Controlled Trial

Shorouk F. Mohamed^{1*}, Soheir M. ElKosery², Nabil M. Fekry³, Afaf M. Botla²

¹Department of Physical Therapy, Al-Agoza Police Hospital, Giza, Egypt.

²Department of Physical Therapy for Women's Health, Faculty of Physical Therapy, Cairo University, Egypt.

³Department of Obstetrics and Gynecology, Police Academy, Cairo, Egypt.

Abstract

Background: A major contributing factor to female infertility is tubal obstruction. Extracorporeal shock waves are acoustic disruptions that travel through a medium, providing energy that helps reduce adhesions and avoid the development of hypertrophic wounds.

Objective: The study's aim was to explore the efficacy of extracorporeal shock waves on fallopian tube adhesions in infertile women.

Materials and Methods: This study involved a total of 52 women, aged 25-35 years, diagnosed with secondary infertility due to fallopian tube adhesions. All participants had a body mass index (BMI) of less than 35 kg/m² and regular menstrual cycles. Participants were recruited from the outpatient clinic of Obstetrics and Gynecology at the Police Authority Hospital in Al Agoza, Giza, Egypt. They were randomly distributed into two groups: control group A, which received medical treatment with chitosan under medical supervision, and study group B, which was treated with the same medical intervention plus extracorporeal shock wave therapy (ESWT) for one session per week for 12 weeks. Fallopian tube patency was assessed before and after the 12-week intervention period using ultrasonography and hysterosalpingography (HSG).

Results: Higher statistically significant improvement in the patency of the fallopian tubes was observed in group B than in group A after treatment ($p = 0.001$) based on both ultrasound and HSG assessments.

Conclusion: The addition of ESWT to medical treatment (chitosan) resulted in superior outcomes in terms of fallopian tube patency, as measured by both ultrasound and HSG, compared to chitosan treatment alone.

Keywords: Extracorporeal shock wave, fallopian tube adhesions, infertility

INTRODUCTION

Infertility is the failure to conceive after a year of consistent, unprotected sexual activity. About 85% of infertile pairings have a known cause. The three most prevalent causes of infertility are tubal disorders, male-related infertility, and ovulatory malfunction (Tan et al., 2019).

About 30% of women experience subfertility due to tubal diseases, with proximal fallopian tube obstruction (FTO) being responsible for 10–25% of these cases. Tubal spasm or intrinsic luminal filling abnormalities, including blood products, small adhesions, or sinus isthmica nodosa, are frequently the cause of proximal FTO (Catena et al., 2016).

While surgery for blocked tubes or adhesions can be effective, it carries several complications, including infection, the creation of additional scar tissue, organ damage, and bleeding (Margaux et al., 2019). Several physical therapy modalities can be effectively used in the treatment of adhesions without resorting to surgery. These modalities include shortwave diathermy, shockwave therapy, ultrasound, laser, electrical stimulation, electroacupuncture, and interferential electrotherapy, all of which have shown positive effects in cases of adhesions (Page et al., 2021).

Shockwave therapy (SWT) has become a popular treatment for various orthopedic conditions, such as incomplete unions of long bone fractures, shoulder calcific tendinitis, lateral epicondylitis of the elbow, and plantar fasciitis. SWT is being utilized more widely to treat adhesive capsulitis, especially when paired with physiotherapy and home exercise regimens (Basoli et al., 2020).

Shockwaves can be generated using three main techniques: electrohydraulic, electromagnetic, and

piezoelectric principles. Each technique offers a different method for generating shockwaves (Cheng et al., 2022). Soft tissue fibrosis is prevented by extracorporeal shockwave therapy (ESWT), which has been shown to have anti-fibrotic properties by dramatically lowering extracellular matrix components (EMC), including fibronectin and type I collagen (Cui et al., 2018).

While some earlier research indicates that SWT can effectively treat intrauterine adhesions in experimental animals (Cheng et al., 2022), no study has examined how SWT affects fallopian tube adhesions in infertile women. Thus, this research intended to assess the efficacy of ESWT in treating fallopian tube adhesions in infertile women.

METHODS

Study Design:

This prospective, randomized controlled trial was carried out at the outpatient clinic of Al-Agoza Police Hospital, Egypt. The practical phase of the study took place over a 6-month period, from December 2024 to May 2025. Prior to their initial evaluation and inclusion in the trial, every participant gave written informed consent after receiving a thorough explanation of the research procedures. In December 2021, Cairo University's Faculty of Physical Therapy Ethics Committee accepted the study protocol (P.T.REC/012/003490). The study has a ClinicalTrials.gov registration number (NCT06755528).

Participants:

The study included 52 women diagnosed with fallopian tube adhesions. Participants were between the ages of 25 and 35 years and had a body mass index (BMI) of less than 35 kg/m². The inclusion criteria required participants to have a diagnosis of fallopian tube adhesions confirmed by a physician, a regular menstrual cycle (ranging from 25 to 34 days), secondary infertility, and a history of a previous cesarean section. Exclusion criteria involved the presence of any gynecological disorders (e.g., uterine prolapse, retroverted uterus, chronic pelvic pain), leukemia, spinal or pelvic tumors, diabetes, hypertension, cardiovascular diseases, and kidney disorders.

Sample Size Calculation:

G*POWER statistical software (version 3.1.9.2; Franz Faul, Universitat Kiel, Germany) was employed to determine the sample size, with an alpha of 0.05, a power of 80%, and an effect size of 0.8, based on the earlier study by Cheng et al. (2022), which predicted a significant difference among groups. According to this computation, 26 people overall would be needed in each group to provide statistically significant outcomes.

Randomization and Blinding:

A computer-generated block randomization program was utilized to carry out the randomization. A 1:1 allocation ratio was used to distribute participants into the experimental or control groups. The use of transparent envelopes that were sealed and consecutively numbered allowed for concealed allocation. A blinded researcher who was not engaged in participant recruitment, gathering data, or treatment administration conducted the randomization process. After randomization, there were no participant withdrawals (Figure 1).

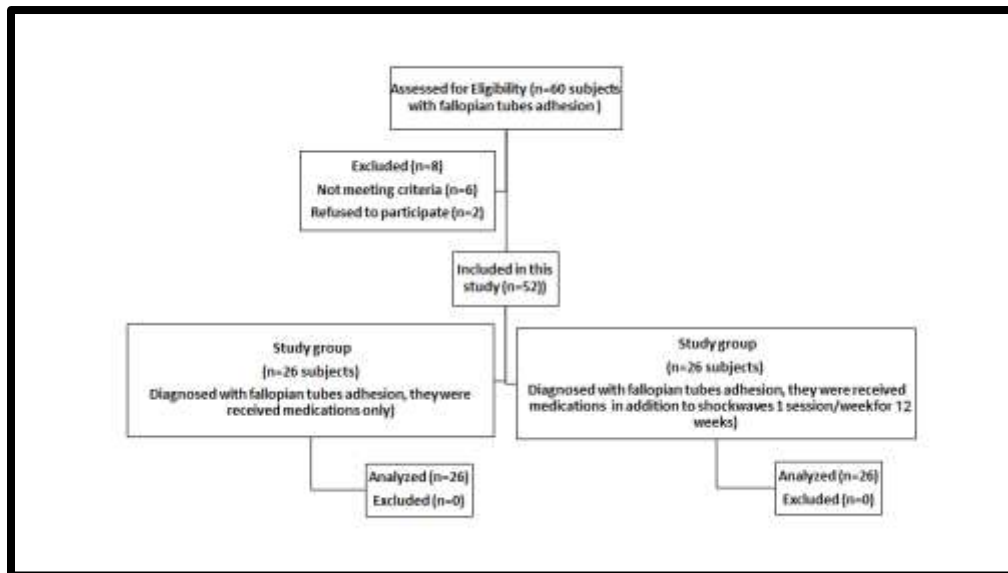


Fig 1: Eligibility Chart

Outcome Measure:

Tubal patency was evaluated using both pelvic abdominal ultrasound and hysterosalpingography before treatment and after the 12-week intervention period for both groups (A and B).

a. Pelvic Abdominal Ultrasound (Model 200700134, W7c1882026):

A Pelvic ultrasound was performed using a vaginal probe, with the patient assuming the lithotomy position. An iodinated solution was regularly used to sanitize the vulva and cervix. The vaginal probe was employed to detect tubal patency on both the right and left sides (Yang et al., 2021).

b. Hysterosalpingography (DMC GmbH, 22335 Hamburg):

The radiographic technique known as hysterosalpingography (HSG) involves injecting a tiny quantity of radio-opaque fluid into the fallopian tubes and uterus. To evaluate intrauterine structures, lesions, and the tubal conditions in the proximal, distal, and intra-pelvic areas, X-rays are then utilized to photograph the uterine cavity and fallopian tubes (Yang et al., 2021).

Treatment interventions:

a. Medication:

Each participant in both groups received medication prescribed by their attending physician. Chitosan, a linear copolymer of glucosamine and N-acetylglycosamine, was used as the treatment. Chitosan injections have the potential to lower postoperative tubal re-obstruction in infertile women and subsequently increase conception rates due to their bacteriostatic characteristics, anti-adhesion properties, and hemostasis effects (Aranaz et al., 2021). Three to seven days after menstruation, interventional recanalization therapy was administered.

b. Shock Wave Therapy:

Shock Wave Parameters: The shockwaves used in this study were characterized by sonic pulses with high peak pressure, reaching up to 100 MPa (500 bar) or higher. There was a wide frequency range, a brief duration (<10 ms), and a quick (<10 ns) pressure rise. The frequency was 5 Hz, and the energy flux density was between 0.09 and 0.16 mJ/mm², with 2,000 impulses per session (Rola et al., 2022).

Treatment Protocol: Each participant in the study group received one session per week for 20 minutes, applied to the affected side (right or left fallopian tube), for a total duration of 3 months. The patient was positioned supine on a treatment plinth, with the body covered by a white sheet, leaving only the treated area exposed. Alcohol-soaked cotton was utilized to clean the treated area's skin, after which the shockwave therapy was applied according to the specified parameters.

Statistical analysis

An unpaired t-test was employed to compare the subject characteristics among groups. The chi-square test (with Fisher's exact test when applicable) was utilized to compare fallopian tube patency between the groups. McNemar's test was utilized to compare before and after the intervention outcomes within each group. All tests were considered statistically significant at a p-value of less than 0.05. The SPSS version 25 for Windows (IBM SPSS, Chicago, IL, USA) was employed for all statistical analyses.

RESULTS

I. Subject characteristics:

Table 1 presents the participant characteristics of both groups. No significant differences were demonstrated across groups in terms of age, weight, height, and BMI ($p > 0.05$).

Table (1). Subject characteristics of both groups:

	Group A	Group B	MD	t- value	p-value
	Mean \pm SD	Mean \pm SD			
Age (years)	30.73 \pm 3.12	30.15 \pm 2.98	0.58	0.68	0.49
Weight (kg)	67.23 \pm 4.06	68.27 \pm 4.72	-1.04	-0.85	0.39
Height (cm)	161.50 \pm 2.82	162.71 \pm 3.20	-1.21	-1.45	0.15
BMI (kg/m ²)	25.75 \pm 0.94	25.78 \pm 1.41	-0.03	-0.10	0.92

SD, Standard deviation; MD, Mean difference; p value, Probability value.

II. Impact of Treatment on Fallopian Tube Patency

• Within-Group Comparison:

No significant difference in fallopian tube patency was observed between before and after intervention in Group A, as measured by both ultrasound and HSG ($p > 0.05$). In contrast, Group B indicated a further significant increase in the number of patent fallopian tubes after treatment compared to before treatment, as measured by both ultrasound and HSG ($p = 0.001$) (Table 2-3).

• Between-Groups Comparison:

No significant difference in fallopian tube patency was noted across groups prior to treatment ($p > 0.05$). However, Group B had significantly more patent fallopian tubes than Group A after treatment, as measured by both ultrasound and HSG ($p < 0.001$) (Table 2-3).

Table (2): Fallopian tube patency measured by ultrasound before and after treatment of both groups:

	Group A	Group B	χ^2 - value	p value
Fallopian tube patency (U.S)	Frequency	Frequency		
Pre treatment				
Patent	0 (0%)	0 (0%)	-	-
Non-patent	26 (100%)	26 (100%)		
Post treatment				
Patent	4 (15%)	21 (81%)	22.26	0.001
Non-patent	22 (85%)	5 (19%)		
X²- value	2.25	19.4		
	P = 0.13	p = 0.001		

X², Chi squared value; p value, Probability value.

Table (3): Fallopian tube patency measured by HSG before and after treatment of both groups:

	Group A	Group B		
Fallopian tube patency (HSG)	Frequency	Frequency	χ^2 -value	p value
Pre treatment				
Patent	0 (0%)	0 (0%)	-	-
Non-patent	26 (100%)	26 (100%)		
Post treatment				
Patent	3 (11.5%)	21 (81%)	25.07	0.001
Non-patent	23 (88.5%)	5 (19%)		
X²-value	1.33	19.4		
	P = 0.25	p = 0.001		

X², Chi squared value; p value, Probability value.

DISCUSSION

Globally, fallopian tube dysfunction is present in about 30% of infertile women. Since in vitro fertilization (IVF) provided a means of overcoming this barrier, this part of infertility was frequently overlooked for many years (Briceag et al., 2015). IVF has become the next treatment choice when conventional therapies fail, and its success rates have increased significantly due to advances in IVF technology. However, despite the advances in IVF, 83–89% of embryos cultured in vitro fail to implant successfully following embryo transfer (Graham et al., 2023).

Recently, research indicated that ESWT has been utilized to address various disorders, including reproductive issues affecting female fertility (Cheng et al., 2022). Thus, this research aimed to investigate the effect of ESWT on fallopian tube adhesions, with pre- and post-treatment fallopian tube patency measured by both ultrasound and HSG.

The current results indicated no significant difference in fallopian tube patency between before and after intervention in Group A ($p = 0.13$), who received only chitosan medication. In contrast, Group B, who received chitosan medication plus ESWT, showed a notable increase in the number of patent fallopian tubes after treatment compared to before treatment ($p = 0.001$). These results indicate that using chitosan combined with ESWT may have a synergistic effect on improving fallopian tube patency. This effect may be attributed to the ability of shockwaves to deliver adequate frequency and amplitude to reach the target tissue, providing sufficient energy to induce tension. Ideally, this is achieved by pre-stretching the target tissue. Haberal et al. (2021) supported this mechanism, suggesting that ESWT positively impacts ECM organization and signaling. Furthermore, Basoli et al. (2020) explained that by activating the P2 receptor and releasing adenosine triphosphates (ATP), ESWT promotes tissue regeneration and cell growth through Erk1/2 stimulation. Additionally, Zhao et al. (2018) demonstrated that both low- and high-energy ESWT applications reduce fibroblast density and suppress hypertrophic wound formation and adhesions.

Our findings align with those of Cheng et al. (2022), who concluded that ESWT combined with platelet-rich plasma (PRP) transplantation is an effective strategy for treating intrauterine adhesions (IUA). According to their research, the combination dramatically decreased inflammation, collagen fibrosis production, and fibrotic scars. This approach may help the IUA-damaged uterine cavity's vascularization, endometrial development, and upregulation of genes related to anti-inflammatory responses.

Our findings are supported by a meta-analysis by Zhang et al. (2018), which discovered that ESWT outperformed traditional wound care alone in terms of its therapeutic impact on adhesion reduction and the healing of both acute and long-term soft tissue wounds. Furthermore, by altering the production of fibrosis-related molecules in fibroblasts generated from individual hypertrophic scars, ESWT inhibits

soft tissue fibrosis and adhesions (Cui et al. 2018).

Earlier studies have demonstrated that chitosan injections have bacteriostatic properties in addition to anti-adhesion and hemostasis benefits, which may help reduce postoperative tubal re-obstruction in infertile women and boost rates of conception. (Huang et al., 2019). However, Chitosan alone may not be sufficient to resolve tubal adhesions effectively. It appears to be more beneficial when combined with other medications or therapeutic modalities (Huang et al., 2022).

Strengths and limitations:

To the author's knowledge, this research is the first to show how ESWT application, a non-invasive procedure with no serious side effects, affects fallopian tube adhesions. This study's randomized design and well-calculated sample size are two of its main strengths. The study did not incorporate patient follow-up. Accordingly, more research with follow-up should be conducted to ascertain the long-term effects of ESWT application on fallopian tube adhesions. As the effects of ESWT application on biomarkers and at the cellular level were not assessed, additional extensive research is required to detect the impacts of ESWT application on fallopian tube adhesions at the cellular level, as well as to assess its clinical implementation and outcomes on conception rate.

CONCLUSION

Extracorporeal shockwaves, in addition to chitosan, have a better impact on fallopian tube patency, even measured by ultrasonic or HSG, than chitosan medication alone.

Author Contributions

SF-M, SM-E, NM-F, and AM-B carried out the research design, data collection, statistical analysis, and interpretation of the data. They cooperated to write, edit, and accept the finalized manuscript before its publication.

Funding: There was no funding for this study.

Data availability:

The authors are prepared to supply the raw data that confirms the results of this article on request and without undue restrictions.

Conflict of Interest: There are no conflicts of interest.

REFERENCES

1. Aranaz I, Alcántara A.R., Civera M.C., Arias C., Elorza B., Caballero A.H., Acosta N. Chitosan: An Overview of Its Properties and Applications. *Polymers*. 2021; 13:3256. Doi: 10.3390/polym13193256.
2. Basoli V, Chaudary S, Crucian S, Santaniello S, Balzano F, Ventura C, Redl H, Dungal P, Maioli M (2020): Mechanical Stimulation of Fibroblasts by Extracorporeal Shock Waves: Modulation of Cell Activation and Proliferation Through a Transient Proinflammatory Milieu. *Cell Transplantation*. 29: 1-10
3. Briceag I, Costache A, Purcarea VL, Cergan R, Dumitru M, Briceag I, Sajin M, Ispas AT (2015): Fallopian tubes - literature review of anatomy and etiology in female infertility. *Journal of Medicine and Life* 8(2):129-131.
4. Catena F, Di Saverio S, Coccolini F, Ansaloni L, De Simone B, Sartelli M, Van Goor H (2016): Adhesive small bowel adhesions obstruction and Evolutions in diagnosis, management and prevention. *World journal of gastrointestinal surgery*. 20:105-115.
5. Cheng,Y.H., Tsai,N.C., Chen,Y.J., Weng,P.L.,et al.(2022).Extracorporeal Shockwave Therapy combined with platelet rich plasma during prevention and therapeutic strages of intraurine adhesion in rat model. *Biomechnics* 10(2),476
6. Cui HS, Hong AR, Kim JB, Yu JH, Cho YS, Joo SY (2018): Extracorporeal shock wave therapy alters the expression of fibrosis-related molecules in fibroblast derived from human hypertrophic scar. *Int J Mol Sci*.19:124.
7. Graham, M. E., Jelin, A., Hoon, A. H., Jr, Wilms Floet, A. M., Levey, E., & Graham, E. M. (2023). Assisted reproductive technology: Short- and long-term outcomes. *Developmental medicine and child neurology*, 65(1), 38-49.
8. Haberal B, Kaya Şimşek E, Akpınar K, Türkbey Şimşek D, Şahintürk F (2021): Impact of radial extracorporeal shock wave therapy in post-laminectomy epidural fibrosis in a rat model. *Jt Dis Relat Surg*. 32(1):162-169.

9. Huang C, He X, Lua W, Chen H, Huang Y (2019): Combined chitosan and Danshen injection for long-term tubal patency in fallopian tube recanalization for infertility. *Drug Delivery and Translational Research*. 9:738-747.
10. Margaux, Becker V., Silver S., Seufert R., Muensterer O.J. The Association of Appendectomy, Adhesions, Tubal pathology, and female infertility. 2019, 32:e2018.00099.
11. Page P, Mistretta C, Thompson J, Brittain K. Musculoskeletal clinical practice guidelines recommended therapeutic interventions. (abstract) Poster Presentation presented at: American Physical Therapy Association -Louisiana; August 27, 2021.
12. Rola P, Włodarczak A, Barycki M, Doroszkó A (2022): Use of the Shock Wave Therapy in Basic Research and Clinical Applications—From Bench to Bedside. *Biomedicines*. 10:568.
13. Tan J, Tannus S, Taskin O, Kan A, Albert AY, Bedaiwy MA. The effect of unilateral tubal block diagnosed by hysterosalpingogram on clinical pregnancy rate in intrauterine insemination cycles: systematic review and meta-analysis. *BJOG*. 2019; 126(2):227-235.
14. Zhao JC, Zhang BR, Hong L, Shi K, Wu WW, Yu JA (2018): Extracorporeal shock wave therapy with low-energy flux density inhibits hypertrophic scar formation in an animal model. *Int J Mol Med*. 2018; 41:1931-1938.