

# Scrotal Skin Tunneling Technique For Surgical Management Of Buried Penis Or Excess Skin Removal In Circumcision, Two Stages Procedure

Ahmed Saad Ahmed<sup>1</sup>, Eman Mohammed Abdelsalam Abdellatif<sup>1</sup>, Ahmed Safaa Ahmed<sup>1</sup>, Abdel Halim M.A. Ali<sup>1</sup>, Mohammed Ahmed Korany<sup>1</sup>

<sup>1</sup>General Surgery department, Faculty of medicine, Beni-Suef University, Beni-Suef, Egypt

---

## Abstract

**Background:** Surgery is a prevalent intervention for pediatric hidden penis. To date, there are several surgical techniques for buried penis.

**Objectives:** to assess efficacy of Scrotal Embedding Tunneling (SET) technique for surgical management of buried penis or excess skin removal in circumcision

**Methods:** A two-stage SET approach was tested in 15 boys (6 months–13 years) over April 2024–April 2025. Patients were assessed immediately postoperative, after 3 months and after 6 months. Follow up and procedure outcomes were assessed by penile length patient satisfaction about size and morphology along with postoperative complications.

**Results:** In table 2 regarding postoperative patient satisfaction about the size of the penis, 6 (40%) were satisfied, 4 (26.7%) were very satisfied, and 20% were unsatisfied, while 2 (13.3%) were very unsatisfied. Regarding postoperative patient satisfaction about the morphology of the penis 6 (40%) were satisfied and 6 (40%) very satisfied, non-satisfaction was reported by 3 cases (20%). Postoperative measurements at 6 months showed significant penile length increase (mean from 2.62 cm to 6.49 cm,  $p < 0.001$ ). Patient satisfaction was moderate: 66.7% were satisfied or very satisfied with size; 80% with morphology. Hairy skin and color differences were common complications (33.3% and  $\sim 20\%$ , respectively), with low rates of infection or hematoma.

**Conclusion:** SET is a flexible, safe, and successful reconstructive procedure for well-chosen patients with a buried penis, facilitating the restoration of penile shaft skin abnormalities without the need for intricate skin grafting.

**Keywords:** Scrotal Embedding Tunneling, buried penis, Pediatrics.

---

## INTRODUCTION

After drastic circumcision, newborns frequently develop deficiencies in their penile skin. When penile skin is removed excessively, circumferential scar tissue may form, which causes the penis to retract proximally. The suprapubic adipose tissue eventually ensnares the penis [1].

A frequent congenital defect of the penis in children, buried penis affects the psychological and behavioral aspects of the affected persons as well as penile development. Adolescent males frequently worry about their penile size if this problem is not addressed. Social shame might result from its effects on gender identity and self-esteem. Some authors have referred to this condition as "small penis syndrome." [2].

The actual prevalence of penile denudation and related entrapment is uncertain, since existing data comprises isolated reports from individual sites. Despite being a seldom seen clinical illness, it may lead to sanitary issues, difficulties in voiding, and sexual dysfunction. Furthermore, it may result in psychological discomfort for both patients and their parents [3].

Small penis syndrome is not solely characterized by the physical appearance of a diminutive penis; more significantly, it adversely impacts boys' self-esteem and contributes to psychological developmental issues, such as anxiety, depression, difficulties in self-presentation, diminished male sexual traits, and challenges related to social integration. This would thus lead to significant psychological issues that need more care [4].

Varieties of surgical procedures have been delineated to rectify penile skin deficit and buried penis [5-9]. Nevertheless, data are limited about the ideal strategy for children exhibiting a persistent deformity after prior treatment efforts and for those with significant cutaneous deficit and for buried penis.

This research sought to evaluate the efficacy of scrotal skin tunneling technique for surgical management of buried penis or excess skin removal in circumcision.

## PATIENTS AND METHODS

### Study participants

This study prospectively investigated 15 buried penis males aged 6–13 years, who had been followed for 6 months after undergoing scrotal tunneling from April 2024 to April 2025.

Children having a confirmed diagnosis of buried penis or those who had extra skin removal after circumcision were included. The exclusion criteria included: children with severe active balanitis; children with a buried penis accompanied by other penile abnormalities; patients undergoing reoperation; or lack of approval for research participation from patients' guardians.

### Preoperative Assessments

The patient had a thorough physical examination and medical history review prior to surgery, as in "Figure 1". Before surgery, patients had their penile size measured, which included the circumference at the mid-shaft and the length of the penile surface.



Figure 1: Preoperative photo show massive skin excision (over circumcision).

### Surgical technique

Scheduled procedures for patients included a two-step penile repair [6]. Relocating the penile shaft via the intrascrotal tube was the first step. Stage two included removing the penis from the intrascrotal tube. While lying on their back, the patient had procedures while under general anesthesia. As a preventative measure, during the induction phase of anesthesia, second-generation cephalosporins were given intravenously.

- Initial stage

The glans penis was deeply sutured using a longitudinal traction suture. A full degloving of the penile skin up to the penopubic junction followed a subcoronal circumferential incision. The extragenital skin had its scar tissue surgically removed.

The next step was to create an intrascrotal tunnel connecting the skin and dartos layer by making a transverse incision in the lower part of the scrotum. It was necessary to implant the penis beneath the scrotal skin before its extraction via the distal tunnel hole. The penile skin was sutured to the scrotal skin at both scrotal openings to prevent penile rotation "Figure 2 & 3".

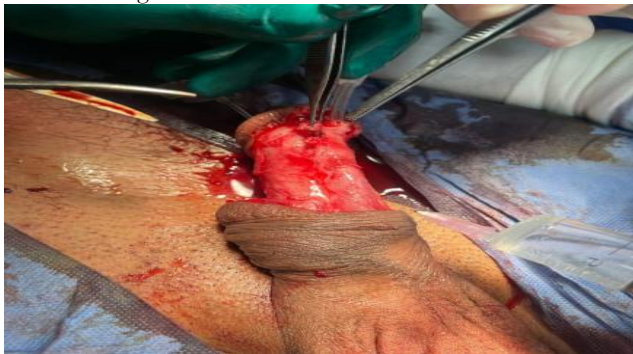

Figure 2: Complete degloving of penis to release fibrous bands before scrotal implantation.

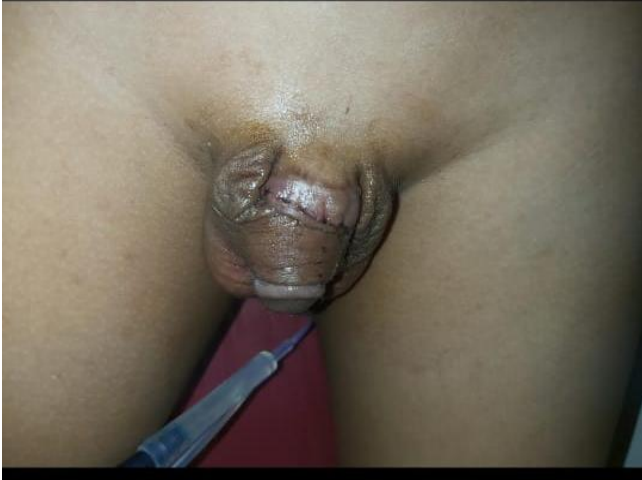

Figure 3: During scrotal tunneling after 2 weeks from implantation.

- Second stage

It took six weeks after the first treatment to do the second stage. The skin around the penis was separated from the surrounding scrotal skin after the penile base was incised twice. Keeping the testicle in its original form required an incision similar to that of a dog's ear. We used longitudinal sutures to fix the scrotal skin defect. Carelessly applying a compressive dressing on the wound sealed it

"Figure 4 & 5".

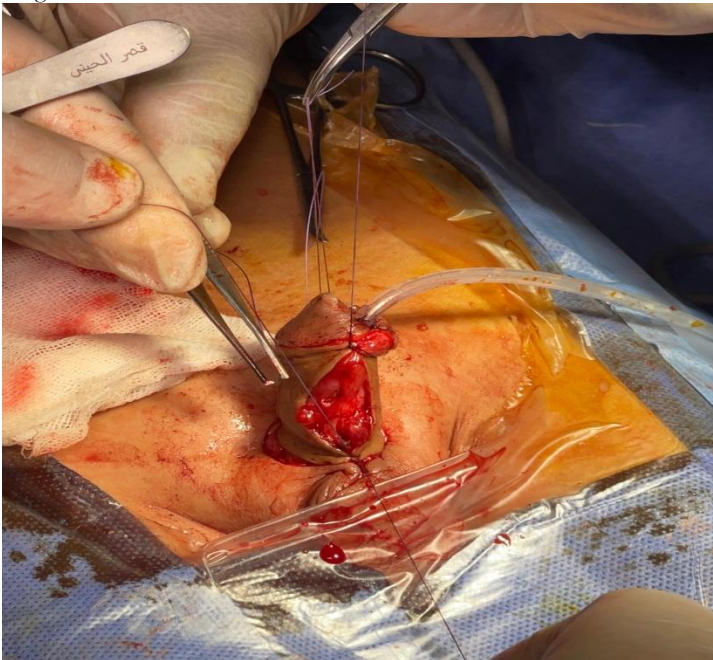


Figure 4: During separation of the penis from the scrotum in the second stage and closure of the scrotum and the dorsal surface of the penis by primary sutures.

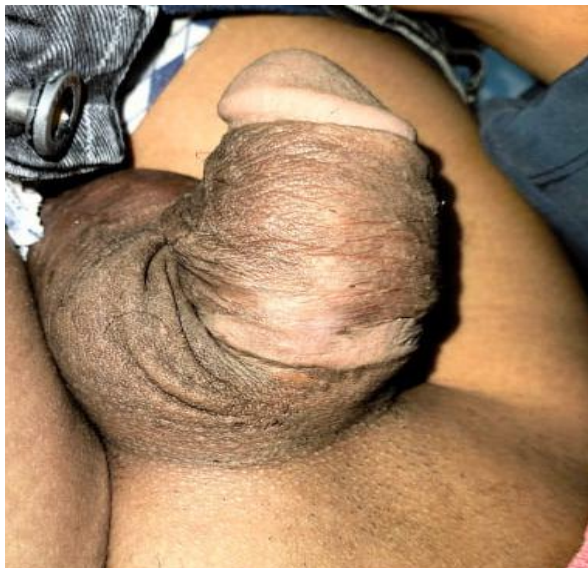

Figure 5: 3 months after separation of the penis from the scrotum.

#### Assessment of patient satisfaction and postoperative complications

We conducted a survey on penile dimensions, morphology and penile hair growth to assess patient satisfaction. **Likert scale** was used to assess satisfaction. Satisfaction was assessed on a scale of 1 to 5, with the following designations: 1, extremely unsatisfactory; 2, unsatisfactory; 3, neutral; 4, acceptable; and 5, very satisfied [10]. The questionnaire was conducted throughout all follow-up sessions. Data about the problems was gathered throughout the patients' postoperative hospitalization and at each follow-up appointment.

#### Ethical statement

All procedures followed the guidelines laid forth in the Declaration of Helsinki. All patients' legal guardians gave their informed permission, and the research has the green light from Beni-Suef University's Ethics Committee (No. FMBSUREC/09072024/Ahmed).

#### STATISTICAL ANALYSIS

We used SPSS version 28 (IBM Corp., Armonk, NY, USA) to code and input the data. For quantitative data, we used measures such as mean, standard deviation, median, minimum, and maximum; for categorical data, we used measures such as count and relative frequency, which provide a better picture of the data. We used the non-parametric Friedman test and the Wilcoxon signed rank test to compare serial measures within each subject. Data were deviated from normal distribution so we used these non parametric methods for paired comparisons. Statistical significance was defined as a p-value below 0.05. All P value was approximated to 3 digits but when it is 0.000 it was written as <0.001.

#### RESULTS

In Table 1 patients ages ranged from 6 months to 13 years and the mean age was  $6.97 \pm 4.31$ . Most patients (80%) suffered from buried penis while 3 cases (20%) were presented with post circumcision bleeding.

Table (1): Age and main complain of patients

Age (year)	Mean $\pm$ SD	6.97 $\pm$ 4.31
	Min-Max	0.50-13.00
	Median	7.00
Complain (n, %)	Buried penis	12 (80.0%)
	Post circumcision bleeding	3 (20.0%)

In table 2 regarding postoperative patient satisfaction about the size of the penis, 6 (40%) were satisfied, 4 (26.7%) were very satisfied, and 20% were unsatisfied, while 2 (13.3%) were very unsatisfied. Regarding postoperative patient satisfaction about the morphology of the penis 6 (40%) were satisfied and 6 (40%) very satisfied, non-satisfaction was reported by 3 cases (20%).

Table (2): Postoperative patient satisfaction about the size and the morphology of the penis

		Count	%
Patient satisfaction about size	very unsatisfactory (grade 1)	2	13.3%
	Unsatisfactory (grade 2)	3	20.0%
	Satisfactory (grade 4)	6	40.0%
	very satisfactory (grade 5)	4	26.7%
	Mean $\pm$ SD	3.47	1.46
Patient satisfaction about morphology	very unsatisfactory (grade 1)	2	13.3%
	Unsatisfactory (grade 2)	1	6.7%
	Satisfactory (grade 4)	6	40.0%
	very satisfactory (grade 5)	6	40.0%
	Mean $\pm$ SD	3.87	1.41

In table 3 the mean preoperative penile length was  $2.62 \pm 1.10$  cm ranging from 1 - 4.5cm, while the mean postoperative penile length after 6 months was  $6.49 \pm 1.94$  cm ranging from 4- 9.5 cm. There were high statistically significant differences between pre and postoperative penile length among patients (p value < 0.001). Penile length after surgery increased from preoperative median 2.5 to postoperative median 6.5 and this is statistically significant. Values of penile length in relation to age was expressed in table (4).

Table (3): Comparison between pre and postoperative penile length among patients

	Mean	Standard Deviation	Median	Minimum	Maximum	P value
penile length preoperative (cm)	2.62	1.10	2.50	1.00	4.50	< 0.001
penile length postoperative (at 6 months)	6.49	1.94	6.50	4.00	9.50	

Table (4): Values of penile length in relation to age

age(year)	penile length preoperative(cm)	penile length postoperative(at 6 months)
0.5	1	4
1	1	4
2	1.5	4.5
3	1.5	4.5
4	2	5
5	2.5	5.5
6	2.3	5.3
7	2.5	6.5

8	3	7
9	3.5	7.5
10	3	8
11	3	8
12	4	9
13	4.5	9.5
13	4	9

In table 5 during the first follow up postoperatively, wound infection was detected in one patient, hematoma was present in another, skin colour difference in 4 patients (26.7%), while hairy skin was the commonest complication as detected in 33.3% of patients. After 3 months, skin colour difference was detected in 4 patients (26.7%), while hairy skin was the commonest complication as detected in 33.3% of patients. After 6 months, skin colour difference was detected in 3 patients (20%), while hairy skin was the commonest complication as detected in 33.3% of patients. The rest of the patients did not suffer any of these complications. No statistical significant difference was present on comparing different follow up periods (p value =.0.467).

Table (5): Distribution of postoperative complications among patients along follow up period

		0 month		3 months		6 months		P value
		Count	%	Count	%	Count	%	
Complications	no	4	26.7%	6	40%	7	46.7%	0.467
	wound infection	1	6.7%	0	0%	0	0%	
	hematoma	1	6.7%	0	0%	0	0%	
	hairy skin	5	33.3%	5	33.3%	5	33.3%	
	skin colour difference	4	26.7%	4	26.7%	3	20%	

In table (6 and &7): 60% of patients with hairy skin were either satisfied or very satisfied about the penile size, while 80% were either satisfied or very satisfied about the penile morphology

Table (6): The relation between occurrence of hairy skin after SET and patient satisfaction about penile size

	patient satisfaction about size									
	grade 1		grade 2		grade 3		grade 4		grade 5	
	Count	%	Count	%	Count	%	Count	%	Count	%
<b>hairy skin</b>	0	0.0%	2	40.0%	0	0.0%	1	20.0%	2	40.0%

very unsatisfactory (grade 1), Unsatisfactory (grade 2), Satisfactory (grade 4), very satisfactory (grade 5)

Table (7): The relation between occurrence of hairy skin after SET and patient satisfaction about penile morphology

	patient satisfaction about morphology									
	grade 1		grade 2		grade 3		grade 4		grade 5	
	Count	%	Count	%	Count	%	Count	%	Count	%
<b>hairy skin</b>	1	20.0%	0	0.0%	0	0.0%	1	20.0%	3	60.0%

very unsatisfactory (grade 1), Unsatisfactory (grade 2), Satisfactory (grade 4), very satisfactory (grade 5)

## DISCUSSION

Burns, various traumas, infections, lymphatic abnormalities, dermatological disorders, and surgical procedures are the main causes of abnormalities in penile skin [11]. Although the precise incidence is uncertain, circumcision may be the major etiological factor causing deficiencies in penile skin. Infants with superficial penile denudation should be questioned about the specifics of the operation (time, surgical method), especially in countries where circumcision is considered a religious requirement. The penis may become trapped in the suprapubic adipose tissue as a result of loss of penile skin, which is often brought on by severe cutaneous excision during circumcision [12].

Sexual dysfunction, recurring balanitis, secondary phimosis, urinary problems, and social embarrassment can all be caused by this concealment. For concealed penises, Maizels et al. [13] proposed a classification scheme. The buried, webbed, and imprisoned penis are its three distinct varieties. The phallus retracts into the suprapubic fat pad because to dysgenetic dartos fascial bands or vestiges of the vestigial cloacal veil, resulting in a congenital buried penis. These underlying problems may be made worse by excessive suprapubic obesity and inadequate penile skin adhesion to the shaft. Extreme circumcision frequently results in iatrogenic conditions in children. Insufficient penile shaft skin resulting from excessive foreskin removal without attaching the penile skin to Buck's fascia might exacerbate the issue and cause scarring. To correct penile skin abnormalities, primary suturing, skin grafting, and local flaps may be employed. Additional procedures can be necessary if the phallus is completely or partially covered with suprapubic adipose tissue. Scar release, graft application, scrotal or penile Z-plasty, dorsal tacking of the suprapubic dermis, and removal of suprapubic adipose tissue are some possible procedures [14–18]. The penis must be free of any tethering or webbing and sufficient penile skin coverage must be guaranteed for a positive surgical result. To stop the penis from retreating downward and away from the shaft skin, the proximal penile skin has to be attached to the underlying fascia [19]. Even for the most skilled surgeons, cases with insufficient penile skin provide a considerable therapeutic challenge. Rotating flaps or tissue replacement grafts may be necessary in severe cases of this deficiency [20].

However, these procedures are technically challenging and need a thorough understanding of reconstructive principles and anatomical details. Because of its pliability and suppleness, the scrotum is an ideal substrate for skin covering, which makes it useful for penile shaft coverings. Moreover, several veins provide blood to the scrotal tissues [21]. The deep and superficial external pudendal vessels, as well as the internal pudendal vessels, provide the linked circulation that makes up the dartos fascia under the penile and scrotal skin. The femoral artery gives birth to the external pudendal arteries, which then branch off to the dorsal penis and expand as the anterior scrotal arteries. The superficial perineal artery, a branch of the internal pudendal artery, vascularizes the posterior region of the scrotum. When the penile shaft is temporarily confined within, it may be considered an accessible vascular bed that might replace insufficient penile skin because of its circulatory supply, tissue characteristics, and physical proximity to the phallus [22].

In the current study; patient's ages ranged from 6 months to 13 years and the mean age was  $6.97 \pm 4.31$ . Most patients (80%) suffered from buried penis while 3 cases (20%) were presented with post circumcision bleeding.

Regarding postoperative patient satisfaction about the size of the penis, 40% were satisfied, 26.7% were very satisfied, and 20% were unsatisfied, while 13.3% were very unsatisfied. Regarding postoperative patient satisfaction about the morphology of the penis 80% were either satisfied or very satisfied, non-satisfaction was reported by 3 cases (20%).

The mean preoperative penile length was  $2.62 \pm 1.10$  cm ranging from 1 - 4.5cm, while The mean postoperative penile length after 6 months was  $6.49 \pm 1.94$  cm ranging from 4- 9.5 cm. There were high statistical significant differences between pre and postoperative penile length among patients ( $p$  value  $< 0.001$ ).

During the first follow up postoperatively, wound infection was detected in one patient, hematoma was present in another, skin colour difference in 4 patients (26.7%), while hairy skin was the commonest complication as detected in 33.3% of patients. Concerning cosmetic results, hair growth may pose a negative issue after scrotal flap surgery. *Laser removal of hair follicles may be proposed to enhance comfort with good results. Surprisingly, in the current investigation 60% of patients with hairy skin were either satisfied or very satisfied about the penile size, while 80% were either satisfied or very satisfied about the penile morphology especially after laser treatment.*

After 3 months, skin colour difference was detected in 4 patients (26.7%), while hairy skin was the commonest complication as detected in 33.3% of patients. After 6 months, skin colour difference was detected in 3 patients

(20%), while hairy skin was the commonest complication as detected in 33.3% of patients. The rest of the patients did not suffer any of these complications. No statistical significant difference was present on comparing different follow up periods ( $p$  value =.0.467).

Similar to this, Zhao et al. [23] restored partial penile abnormalities brought on by tumor resection, animal attacks, and circumcision using scrotal skin flaps. In addition to attaining the best possible aesthetic results, they found that all patients' erectile and sensory functions were maintained. The importance of scrotal skin flaps with a dual vascular supply was also underlined. The vascular network of the scrotal skin is made up of the branches of the internal and external pudendal arteries that provide blood to the scrotal wall. As a result, flap necrosis is rare and the skin flaps may survive because of the fascial vascular network [23]. These findings highlight how important the scrotal vasculature is, particularly for reconstructive procedures. In a review article, Kelemen et al. [24] evaluated a number of surgical techniques for people with tissue deficiencies and penile deformities. The best cosmetic results were observed when the penis was temporarily implanted into the scrotum to replace the lost skin. This technique was used to 10 adult patients with a buried penis by Zucchi et al. [25]. After 20 months, which was the median follow-up time, they reported positive functional and cosmetic results. On the visual analog scale for patient satisfaction, 97 was the median score. Additionally, the patients who took part in the study by Ziylan et al. [6] thought the scrotal skin was more aesthetically pleasing than the native skin since it was somewhat thicker. Shaft skin was severely lacking in our patients. The phallus's deficiency and therefore buried look were ascribed to non-healing ischemia necrosis and severe circumcision. The skin abnormality was successfully concealed by the penis's temporary placement inside the scrotal tube. Direct healing of the skin flaws was possible when the penile shaft was dissected from the tunnel. Both people had good cosmetic results in the end.

Kara et al. [27] assessed the feasibility and long-term functional effects of surgical repair for adult patients with buried penis resulting from problems of childhood circumcision, using autologous split-thickness skin grafts (STSG). During follow-up visits, 12 patients (92%) expressed a degree of satisfaction, occurring 44 months (range: 10–61 months) post-surgery. The differences with our results may be attributed to the type of patient as our patients were kids with less expressive ability unlike adults.

Previous research indicates that local tissue was augmented through tissue expansion (TE). Harris and colleagues [28] employed tissue expansion (TE) and full-thickness skin graft (FTSG) for penile reconstruction after shaft skin excision due to excessive circumcision in 12 patients. All 12 patients attained success, including six who experienced complications. The median age at reconstruction was 10.6 years, with a range of 0.8 to 28.0 years. The median follow-up duration was 6.6 months. Following the resurfacing of the penis, patients experienced an average penile length increase of 3.0 cm (range 1.7–4.3 cm). All four individuals who reached maturity expressed satisfaction with penile appearance and were capable of engaging in sexual intercourse. Injury transpired during neonatal circumcision in nine instances and after repeat circumcision for inadequate foreskin removal in three. Previous results aligned with ours in most findings; nevertheless, the types of problems mostly included lymphedema. Both STSG and FTSG have been effectively used in limited cases of post-circumcision trapped penis, resulting in superior esthetic outcomes and sustained satisfaction over time [17, 29,30].

In a previous research [31], sixteen patients had surgical intervention for acquired buried penis (ABP) with penile liberation, escutcheonectomy, and split-thickness skin grafting. Concurrent scrotoplasty and urethroplasty were performed in some situations. The follow-up period lasted 90 days, during which 25% of cases were complicated; however, split-thickness skin grafts demonstrated both 100% and technical success.

Our findings indicate that scrotal embedding, which provides elastic, thick, and vascular skin covering, is advantageous for adolescent penile skin deficiencies that are mostly caused by severe circumcision resection.

The main limitations of our study are the small sample size, the short follow-up period and lack of control group.

## CONCLUSIONS

However, SET may be an effective option for surgeons who are not very experienced in reconstructive penile surgery and for those who treat iatrogenic, resistant patients with localized skin deficiency. In iatrogenic cases with inadequate shaft skin, SET may be utilized to repair the penile shaft. The reasons for moving forward with SET in

our group was buried penis, which persisted following conservative and/or surgical measures. For iatrogenic, refractory penile skin deficiencies, a two-stage procedure that makes use of the scrotal vascular and surgical simplicity could offer a more conclusive cure. Larger sample size with longer short follow-up period and addition of a control group, are recommended in the future researches.

## REFERENCES

1. Anandan L, Mohammed A. Surgical management of buried penis in adults. *Central European Journal of Urology*. 2018 Sep 22;71(3):346.
2. Fahmy M. *Congenital anomalies of the penis*. Cham: Springer International Publishing; 2017 Feb 10.
3. McLennan GP, Feber KM, Kass EJ. Abnormalities of the penis and scrotum. In *The Kelalis-King-Belman Textbook of Clinical Pediatric Urology* 2018 Sep 3 (pp. 1268-1296). CRC Press.
4. Wood D, Woodhouse C. Penile anomalies in adolescence. *The Scientific World Journal*. 2011;11(1):614-23.
5. Han DS, Jang H, Youn CS, Yuk SM. A new surgical technique for concealed penis using an advanced musculocutaneous scrotal flap. *BMC urology*. 2015 Dec;15:1-5.
6. Ziyilan O, Acar Ö, Özden BC, Tefik T, Dönmez Mİ, Oktar T. A practical approach for the correction of iatrogenic penile skin loss in children: Scrotal embedding technique. *Turkish journal of urology*. 2015 Jun 18;41(4):235.
7. Cui X, Gao BJ, Chen L, Huang WH, Zhou CM. A modified fixation technique for the treatment of buried penis in children. *Asian Journal of Andrology*. 2023 Jan 1;25(1):78-81.
8. Liu F, Lin T, He D, Wei G, Liu J, Liu X, Hua Y, Zhang D, Lu P, Wu S, Li X. New technique for the treatment of buried penis in children. *Urology*. 2016 Feb 1;88:166-9.
9. Westerman ME, Tausch TJ, Zhao LC, Siegel JA, Starke N, Klein AK, Morey AF. Ventral slit scrotal flap: a new outpatient surgical option for reconstruction of adult buried penis syndrome. *Urology*. 2015 Jun 1;85(6):1501-4.
10. Belay Bizuneh, Yosef et al. "Assessment of Patient's Satisfaction and Associated Factors regarding Postoperative Pain Management at the University of Gondar Compressive Specialized Hospital, Northwest Ethiopia." *Pain research & management* vol. 2020 8834807. 12 Nov. 2020, doi:10.1155/2020/8834807
11. Fortier E, Cerruti A, Clec'h CL, Bigot P. Review of cutaneous penile lesions. *Journal of Clinical Urology*. 2018 Nov;11(6):429-39.
12. Iacob SI, Feinn RS, Sardi L. Systematic review of complications arising from male circumcision. *BJUI compass*. 2022 Mar;3(2):99-123.
13. Maizels M, Zaontz M, Donovan J, Buschnick PN, Firlit CF. Surgical correction of the buried penis: description of a classification system and a technique to correct the disorder. *J Urol* 1986;136:268-71.
14. Joseph VT. A new approach to the surgical correction of buried penis. *J Pediatr Surg* 1995;30:727-9.
15. Cromie WJ, Ritchey ML, Smith RC, Zagaja GP. Anatomical alignment for the correction of buried penis. *J Urol* 1998;160:1482-4.
16. Hinman F. Surgical management of microphallus. *J Urol* 1971;105:901-4
17. Gillett MD, Rathbun SR, Husmann DA, Clay RP, Kramer SA. Split-thickness skin graft for the management of concealed penis. *J Urol* 2005;173:579-82.
18. Alter GJ, Ehrlich RM. A new technique for correction of the hidden penis in children and adults. *J Urol* 1999;161:455-9.
19. Herndon CD, Casale AJ, Cain MP, Rink RC. Long-term outcome of the surgical treatment of concealed penis. *J Urol* 2003;170:1695-7.
20. Casale AJ, Beck SD, Cain MP, Adams MC, Rink RC. Concealed penis in childhood: a spectrum of etiology and treatment. *J Urol* 1999;162:1165-8.
21. Fahmy MA. *Anatomy of the scrotum*. In *Normal and Abnormal Scrotum* 2021 Dec 1 (pp. 65-90). Cham: Springer International Publishing.
22. Cavalie G, Bellier A, Marnas G, Boisson B, Robert Y, Rabattu PY, Chaffanjon P. Anatomy and histology of the scrotal ligament in adults: inconsistency and variability of the gubernaculum testis. *Surgical and Radiologic Anatomy*. 2018 Apr;40:365-70.
23. Zhao YQ, Zhang J, Yu MS, Long DC. Functional restoration of penis with partial defect by scrotal skin flap. *J Urol* 2009;182:2358-61.
24. Kelemen Z. Reconstructive surgery of penile deformities and tissue deficiencies. *Orv Hetil* 2009;150:1023-9.
25. Zucchi A, Perovic S, Lazzeri M, Mearini L, Costantini E, Sansalone S, et al. Iatrogenic trapped penis in adults: New, simple 2-stage repair. *J Urol* 2010;183:1060-3.
26. Ziyilan O, Acar Ö, Özden BC, Tefik T, Dönmez Mİ, Oktar T. A practical approach for the correction of iatrogenic penile skin loss in children: Scrotal embedding technique. *Turkish journal of urology*. 2015 Jun 18;41(4):235.
27. Kara Ö, Teke K, Çiftçi S, Üstüner M, Uslubaş AK, Bosnalı E, Çulha MM. Buried penis in adults as a complication of circumcision: surgical management and long-term outcomes. *Andrologia*. 2021 Mar;53(2):e13921.
28. Harris TG, Khandge P, Wu WJ, Leto Barone AA, Steinberg JP, Redett III RJ, Gearhart JP. Surgical approach to penile reconstruction for shaft skin excision from circumcision. *Pediatric surgery international*. 2023 Feb 23;39(1):138.
29. Elbatarny AM. Surgical treatment of postcircumcision trapped penis. *Annals of Pediatric Surgery*. 2014;10(4):119-24.
30. Harris TG, Maruf M, Barone AA, Redett III RJ, Gearhart JP. Utility of skin grafting and tissue expansion in penile reconstruction for the exstrophy-epispadias complex. *Urology*. 2020 Feb 1;136:231-7.

31. Erpelding SG, Hopkins M, Dugan A, Liao JY, Gupta S. Outpatient surgical management for acquired buried penis. Urology. 2019 Jan 1;123:247-51.