

# A Prospective Comparative Study Of Proximal Femoral Nailing And Bipolar Hemiarthroplasty In Comminuted Intertrochanteric Fractures

<sup>1</sup>Dr. Chethan Gowda M, <sup>2</sup>Dr. Mahesh D V, <sup>3</sup>Dr. Rajeevratna Suresh Naik, <sup>4</sup>Dr. Vineeth K S

<sup>1</sup>Post Graduate, Department of Orthopaedics, Adichunchanagiri Institute of Medical Sciences, Adichunchanagiri University, B.G. Nagara, Karnataka, India.

<sup>2</sup>Professor and HOD, Department of Orthopaedics, Adichunchanagiri Institute of Medical Sciences, Adichunchanagiri University, B.G. Nagara, Karnataka, India.

<sup>3</sup>Assistant Professor, Department of Orthopaedics, Adichunchanagiri Institute of Medical Sciences, Adichunchanagiri University, B.G. Nagara, Karnataka, India.

<sup>4</sup>Post Graduate, Department of Orthopaedics, Adichunchanagiri Institute of Medical Sciences, Adichunchanagiri University, B.G. Nagara, Karnataka, India.

---

## Abstract

**Introduction:** Comminuted intertrochanteric fractures in the elderly present a significant surgical challenge, balancing the goal of early mobilization against the risks of implant failure and complications associated with osteoporosis. While proximal femoral nailing (PFN) is a standard osteosynthesis technique, bipolar hemiarthroplasty (BHA) has emerged as an alternative promising immediate stability and early weight-bearing. This study aims to compare the functional outcomes of these two surgical modalities.

**Methods:** A prospective comparative study was conducted from February 2023 to February 2025, involving 40 elderly patients ( $\geq 60$  years) with comminuted intertrochanteric fractures (AO/OTA 31-A2, Evans type III-V). Patients were randomly allocated to either PFN ( $n=20$ ) or cemented BHA ( $n=20$ ) groups. Intraoperative parameters (duration of surgery, blood loss, incision length), postoperative complications, time to mobilization, and functional outcomes assessed via the Harris Hip Score (HHS) at six months were evaluated and compared.

**Results:** The mean age of participants was 72.8 years, with a female predominance (60%). Trivial fall was the most common mechanism of injury (82.5%). The PFN group demonstrated significant advantages in intraoperative metrics, including shorter surgical duration ( $70 \pm 8.16$  vs.  $120 \pm 10.80$  minutes,  $p < 0.001$ ), less blood loss ( $131.5 \pm 31.97$  vs.  $214.5 \pm 31.48$  ml,  $p = 0.001$ ), and smaller incisions ( $7.5 \pm 1.35$  vs.  $12.6 \pm 1.26$  cm,  $p < 0.001$ ). Conversely, the BHA group achieved significantly earlier full weight-bearing (30 vs. 60 days,  $p = 0.0015$ ). At the six-month follow-up, the mean HHS was excellent in the BHA group ( $85.9 \pm 6.09$ ) and good in the PFN group ( $82.95 \pm 5.80$ ), though this difference was not statistically significant ( $p = 0.134$ ). The PFN group showed a superior range of motion ( $100^\circ$  vs.  $86^\circ$ ,  $p = 0.0015$ ). Complication rates were comparable between groups (PFN: 6, BHA: 5), with wound infection and limb length discrepancy being the most common.

**Conclusion:** Both PFN and BHA are effective treatments for comminuted intertrochanteric fractures in the elderly, yielding good functional outcomes. The choice of procedure should be individualized. PFN offers a less invasive approach with better hip mobility, leveraging biological healing. BHA facilitates dramatically earlier weight-bearing, which is crucial for mitigating the risks of prolonged immobility in frail patients. The decision should be guided by fracture geometry, bone quality, surgical expertise, and, most importantly, the patient's physiological demands and lifestyle requirements.

**Key words:** intertrochanteric fracture, osteoporosis, proximal femoral nail (pfn), bipolar hemiarthroplasty, harris hip score, functional outcome, elderly patients

---

## INTRODUCTION

Intertrochanteric fractures are one of the leading causes of morbidity and mortality in the elderly population. The incidence of hip fractures is approximately 80 per 100,000 individuals, with intertrochanteric fractures constituting nearly 45% of these cases [1]. Unstable comminuted intertrochanteric fractures in this age group are particularly associated with high morbidity and mortality [2]. Although internal fixation techniques have improved outcomes, factors such as comminution, osteoporosis, and fracture instability often delay the resumption of full weight-bearing [3].

These fractures commonly occur following trivial falls and result from both direct and indirect forces. They represent nearly half of all proximal femoral fractures [4]. Direct forces act along the femoral axis or on the greater trochanter, whereas indirect forces involve the pull of the iliopsoas on the lesser trochanter and the abductors on the greater trochanter. Intertrochanteric fractures are most frequently seen in patients over 60

years of age and occur three times more often in women than in men, largely due to postmenopausal osteoporosis and decreased activity levels. Severe osteoporosis in this group predisposes to fractures even after minimal trauma. Patients with extracapsular intertrochanteric fractures tend to be older, with the average age ranging between 60 and 75 years [5]. The presence and degree of osteoporosis can be radiographically evaluated using Singh's index, which assesses the trabecular pattern of the proximal femur [6].

Before the development of modern fixation devices, management was primarily nonoperative, involving prolonged traction and bed rest for 10–12 weeks, followed by extended ambulation training. This approach was linked to serious complications such as pressure sores, urinary tract infections, contractures, pneumonia, and thromboembolic events, resulting in high mortality. In addition, fractures often healed with varus deformity and shortening due to ineffective counteraction of deforming muscular forces.

Currently, surgical intervention is preferred to minimize the risks associated with conservative management, promote early mobilization, and restore function [3]. Proximal femoral nailing offers stable fixation but may require postoperative protection to prevent implant-related complications. Bipolar hemiarthroplasty, on the other hand, has been advocated for select cases, particularly in elderly osteoporotic patients, as it facilitates early weight-bearing and rehabilitation.

## **MATERIALS AND METHODS**

This was a prospective comparative study conducted in the Department of Orthopaedics, Adichunchanagiri Institute of Medical Sciences, B.G. Nagara, between February 2023 and February 2025. A total of 40 patients with comminuted intertrochanteric fractures of the femur were included. Patients were randomly allocated into two groups: those treated with proximal femoral nailing (PFN) and those treated with bipolar hemiarthroplasty.

### **Inclusion criteria**

- Cases of comminuted intertrochanteric femur fractures in the age group above 60 years.
- IT fractures under classification AO 31 A2
- Evans's classification types 3 4 5
- Closed fractures, open type 1 fractures
- All patients medically fit for surgery
- Fractures within 3 weeks

### **Exclusion criteria**

- Intertrochanteric fractures in patients aged less than 60 years of age
- Open type 2, 3 fractures
- IT fractures classification AO (31.A1, 31.A3)
- Evans types 1 2
- Fracture due to tumor or any other pathological cause.
- Fractures >3 weeks
- Seriously ill patients and Pts not fit for surgery

### **Surgical procedure**

Patients were randomly allocated into two groups: proximal femoral nailing (PFN) or bipolar hemiarthroplasty.

#### **Proximal Femoral Nailing (PFN)**

Patients were positioned supine on a fracture table with traction applied to achieve closed reduction under fluoroscopic guidance. A standard lateral approach to the proximal femur was used. After entry through the tip of the greater trochanter, guidewire placement was confirmed in both anteroposterior and lateral views. Sequential reaming was performed, and the appropriate-sized nail was inserted. Fixation was achieved using a de-rotation screw and a lag screw passed into the femoral neck and head, with distal locking screws inserted as required. Care was taken to maintain proper tip-apex distance and avoid varus malalignment. Wound closure was performed in layers over a suction drain.

#### **Bipolar Hemiarthroplasty**

Patients were positioned in the lateral decubitus position. A standard posterior approach to the hip was performed. Following capsulotomy and exposure of the joint, the femoral head and neck were excised. The canal was prepared using sequential broaches, and appropriate trial components were used to determine leg length and offset. A cemented bipolar prosthesis was inserted in most cases, and fixation was confirmed intraoperatively. The capsule and short external rotators were repaired to minimize the risk of dislocation. Wound closure was performed in layers over a suction drain.

#### **Intraoperative considerations**

In both groups, duration of surgery, incision length, and intraoperative blood loss were recorded. Meticulous hemostasis was ensured. Patients received prophylactic antibiotics at induction, and tranexamic acid was used as per institutional protocol to reduce blood loss.

#### Postoperative protocol

Postoperative management included antibiotics, analgesics, and thromboprophylaxis. Mobilization was initiated as tolerated, depending on the surgical method.

#### Outcome assessment

Patients were followed at regular intervals up to 12 months. Functional outcome was assessed using the Harris Hip Score (HHS). Additional parameters evaluated were postoperative pain, range of motion, time to mobilization, and complications such as infection, implant failure, and dislocation.

#### Statistical analysis

Data were analysed using appropriate statistical methods. Continuous variables were expressed as mean  $\pm$  standard deviation, and categorical variables as percentages. Comparisons between groups were made using the chi-square test for categorical variables and the student's t-test for continuous variables. A p-value  $< 0.05$  was considered statistically significant.

## RESULTS

A total of 40 patients with comminuted intertrochanteric fractures were included in the study, with 20 patients each in the proximal femoral nailing (PFN) group and the bipolar hemiarthroplasty group. The mean age of the study population was 72.8 years, with most cases occurring between 60 and 65 years of age. Females constituted 60% of the cases, and the right side was more commonly affected (60%) than the left. The most frequent mode of injury was a trivial fall, accounting for 82.5% of cases.

The intraoperative parameters showed clear differences between the two groups. The mean length of incision was shorter in the PFN group, whereas the mean duration of surgery was longer in the bipolar hemiarthroplasty group. Intraoperative blood loss was significantly greater in the hemiarthroplasty group when compared with the PFN group. Postoperative recovery patterns also varied between the groups. Patients in the PFN group reported lower postoperative pain and demonstrated better recovery of hip range of motion. However, patients who underwent bipolar hemiarthroplasty were able to commence weight-bearing and ambulation earlier than those treated with PFN, reflecting the inherent stability provided by the prosthesis.

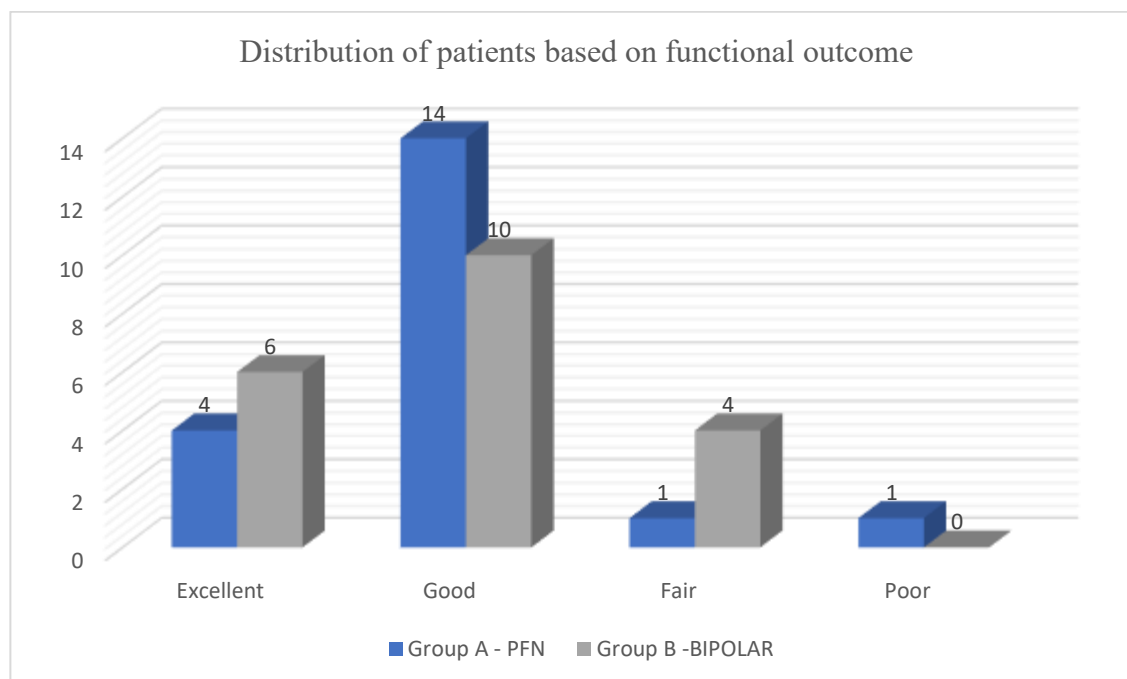
Functional outcomes were assessed using the Harris Hip Score (HHS). At the final follow-up, the mean HHS was  $82.95 \pm 5.80$  in the PFN group and  $85.9 \pm 6.09$  in the bipolar hemiarthroplasty group. Although the bipolar group demonstrated slightly higher scores, the difference was not statistically significant ( $p = 0.134$ ). Complications were noted in both groups, with a total of six complications in the PFN group and five complications in the bipolar group. In the PFN group, complications included malunion, varus collapse, and screw-related problems, while in the hemiarthroplasty group, complications included superficial infection, dislocation, and prosthetic loosening.

**Table 1: Comparison of demographic characteristics between study groups**

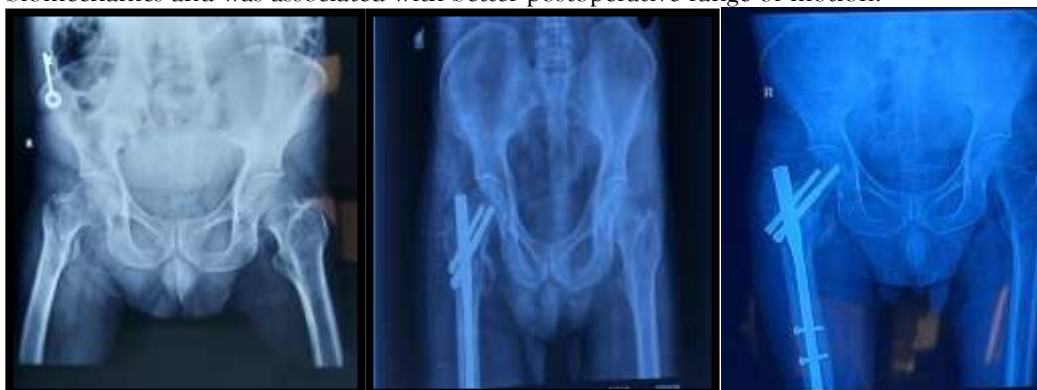Characteristics	PFN group (n=20)	Bipolar group (n=20)	p-value
Age (years), Mean $\pm$ SD	72.4 $\pm$ 6.8	73.2 $\pm$ 7.1	0.68
Sex, n (%)			
Male	8 (40)	8 (40)	1.0
Female	12 (60)	12 (60)	
Affected side, n (%)			
Right	12 (60)	12 (60)	1.0
Left	8 (40)	8 (40)	
Mode of injury, n (%)			
Trivial fall	16 (80)	17 (85)	0.71
RTA/others	4 (20)	3 (15)	

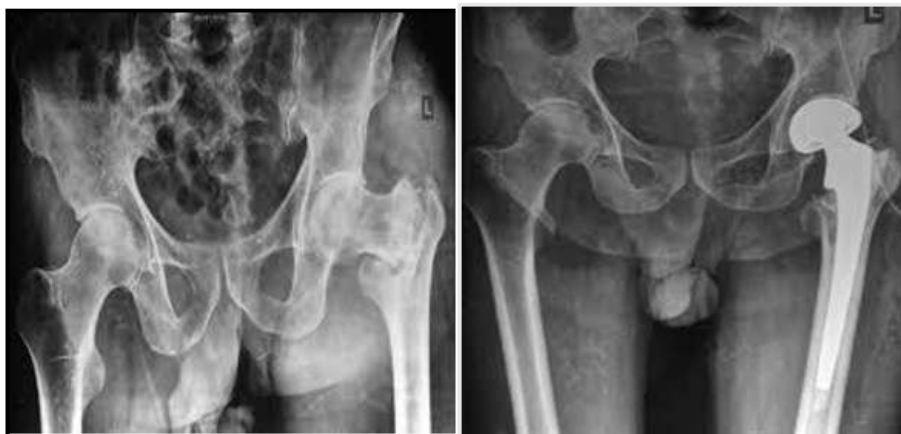**Table 2: Comparison of intraoperative and postoperative outcomes between study groups**

Results	PFN group (Mean $\pm$ SD)	Bipolar group (Mean $\pm$ SD)	p-value
Operation time (mins)	72.5 $\pm$ 7.6	95.4 $\pm$ 9.2	<0.001
Blood loss (ml)	110.3 $\pm$ 18.5	220.6 $\pm$ 30.2	<0.001
Duration of hospital stay (days)	7.1 $\pm$ 1.5	9.2 $\pm$ 1.8	0.002
Time to mobilization (days)	7.8 $\pm$ 2.1	3.5 $\pm$ 1.2	<0.001
Harris Hip Score (12 months)	82.95 $\pm$ 5.80	85.9 $\pm$ 6.09	0.134
Complications, n (%)	6 (30)	5 (25)	0.73

**Graph 1: Distribution of patients based on functional outcome**

Overall, both PFN and bipolar hemiarthroplasty demonstrated good functional outcomes for comminuted intertrochanteric fractures. Hemiarthroplasty allowed earlier mobilization, whereas PFN preserved hip biomechanics and was associated with better postoperative range of motion.

**Figure 1: Pre-op x-ray: immediate post op x-ray: x-rays 6 months follow-up**



**Figure 2: Pre-op x-ray: immediate post op x-ray**

## DISCUSSION

Comminuted intertrochanteric fractures in the elderly remain a major challenge in orthopaedic practice due to associated osteoporosis, medical comorbidities, and the need for early mobilization. Historically, nonoperative management with traction and prolonged immobilization was the standard of care, but this was associated with high complication rates including pressure sores, pneumonia, thromboembolism, and joint contractures, resulting in significant mortality [1–3]. Surgical intervention has since become the preferred modality of treatment to enable early mobilization and reduce complications.

Proximal femoral nailing has been widely accepted as a standard fixation method for unstable intertrochanteric fractures because it provides a biomechanically stable construct, requires a minimally invasive approach, and preserves fracture biology [4–6]. However, in elderly patients with severe comminution and osteoporosis, the risk of implant-related complications such as screw cut-out, varus collapse, and delayed mobilization remains significant [7,8]. In the present study, although PFN provided better postoperative hip mobility and less pain, delayed full weight-bearing was necessary to prevent implant failure, which may contribute to higher morbidity in this age group.

On the other hand, bipolar hemiarthroplasty has been proposed as an alternative, particularly in elderly osteoporotic patients, as it allows immediate or early weight-bearing and avoids complications of prolonged recumbency [9–11]. In this study, patients in the hemiarthroplasty group achieved earlier ambulation, and the mean Harris Hip Score at final follow-up was slightly higher compared to the PFN group, though the difference was not statistically significant. Similar findings have been reported in other comparative studies where hemiarthroplasty demonstrated earlier rehabilitation and return to pre-injury activity levels, while long-term functional outcomes remained comparable to PFN [12–15].

The complication profile differed between the two procedures. PFN was associated with mechanical complications such as varus collapse and malunion, whereas hemiarthroplasty showed a higher risk of wound-related complications, dislocation, and prosthetic loosening. These observations are consistent with previous reports that have highlighted the trade-off between implant-related failures in osteosynthesis and prosthesis-related complications in arthroplasty [16–18].

The current study reaffirms that both PFN and bipolar hemiarthroplasty are effective options in the management of comminuted intertrochanteric fractures. The choice of procedure should be individualized based on fracture morphology, bone quality, patient age, comorbidities, and functional demands. PFN is advantageous in preserving the native hip joint and providing better range of motion, while hemiarthroplasty offers the benefit of immediate mobilization, which is critical in frail elderly patients to prevent systemic complications.

Limitations of this study include the relatively small sample size and short follow-up period. Larger multicentric studies with longer follow-up are required to further validate these findings and establish clear guidelines for procedure selection in this patient population.

## CONCLUSION

Both proximal femoral nailing and bipolar hemiarthroplasty provide satisfactory functional outcomes in the management of comminuted intertrochanteric fractures in elderly patients. Hemiarthroplasty allows earlier

mobilization and reduces the risks associated with prolonged recumbency, while proximal femoral nailing preserves the native hip joint and offers better postoperative range of motion once union is achieved. The choice of procedure should be tailored to individual patient factors such as bone quality, fracture geometry, comorbidities, and functional demands.

In conclusion, both proximal femoral nailing and bipolar hemiarthroplasty remain valid options in the surgical management of comminuted intertrochanteric fractures in the elderly. The surgical strategy should be individualized to optimize recovery, reduce morbidity, and improve quality of life. Larger multicentric studies with longer follow-up are needed to confirm these observations and provide stronger evidence for developing standardized treatment guidelines.

## REFERENCES

1. Zuckerman JD. Hip fracture. *N Engl J Med*. 1996;334(23):1519-1525.
2. Jensen JS. Trochanteric fractures: an epidemiological, clinical, and biochemical study. *Acta Orthop Scand Suppl*. 1981;188:1-109.
3. Bergman GD, Winkquist RA, Mayo KA, Henson SI Jr. Subtrochanteric fracture. *J Am Acad Orthop Surg*. 1994;2(3):150-156.
4. Koval KJ, Zuckerman JD. Hip fractures: evaluation and treatment of intertrochanteric fractures. *J Am Acad Orthop Surg*. 1994;2(3):150-156.
5. Norton PL. Intertrochanteric fractures. *Clin Orthop Relat Res*. 1969;66:77-81.
6. Singh M, Maini PS. Changes in trabecular pattern of the upper end of femur as an index to osteoporosis. *J Bone Joint Surg Am*. 1970;52(3):457-467.
7. Von Langenbeck J, Groves J, Smith-Petersen J, Johanson G, Küntscher G, Neufeld C. Nailing of intertrochanteric fractures. In: Gustilo RB, Kyle RF, Templeman D, eds. *Fractures and Dislocations*. Vol 2. St. Louis, MO: Mosby; 1993:783-784.
8. DeLee JC, Lawson T, Thompson J. In: Rockwood CA, Green DP, Bucholz RW, eds. *Rockwood and Green's Fractures in Adults*. 3rd ed. Vol 2. Philadelphia: Lippincott; 1991:1481-1651.
9. Jewett EL. One-piece angle nail for trochanteric fractures. *J Bone Joint Surg Am*. 1941;23:803-810.
10. Murray RC, Frew JFM. Trochanteric fractures of the femur. *J Bone Joint Surg Br*. 1949;31B(2):204-219.
11. Evans EM. The treatment of trochanteric fractures of the femur. *J Bone Joint Surg Br*. 1949;31B(2):190-203.
12. Dimon JH, Hughston JC. Unstable intertrochanteric fracture of the hip. *J Bone Joint Surg Am*. 1967;49A:440-450.
13. Küntscher G. A new method of treatment of pertrochanteric fractures. *Proc R Soc Med*. 1970;63:1120.
14. Uzun M, Ertürer E, Öztürk I, Akman S, Seçkin F, Özçelik İ. Long-term radiographic complications following treatment of unstable intertrochanteric femoral fractures with the proximal femoral nail and effects on functional results. *Acta Orthop Traumatol Turc*. 2009;43(6):457-463.
15. Sancheti KH, Sancheti PK, Shyam AK, Patil S, Dhariwal Q, Joshi R. Primary hemiarthroplasty for unstable osteoporotic intertrochanteric fractures in the elderly: a retrospective case series. *Indian J Orthop*. 2010;44(4):428-434.
16. Bansal K, Singh J, Patel M, Kumar S. Proximal femur nail vs cemented bipolar prosthesis in unstable intertrochanteric femur fractures in elderly: a prospective study. *Int J Orthop Sci*. 2019;5(2):740-745.
17. Saraf H, Munot S. Comparative study of PFN antirotation vs bipolar hemiarthroplasty in unstable senile intertrochanteric fractures. *Indian J Orthop Surg*. 2018;4(4):380-385.
18. Chandra P, Reddy P, Kumar V, Kumar S. A comparative study between cemented hemiarthroplasty and proximal femoral nail in proximal femur fractures in elderly patients. *Indian J Orthop Surg*. 2017;3(3):275-281.