

The Use Of Advanced Imaging Techniques In Diagnosing Equine Musculoskeletal Disorders

Dr. Souvik Sur^{1*}, Dr. Pradeep Kumar Dohare², Kalyani Tiwari³, Dr. S. Padmavathi⁴, Dr Sukanta Bandyopadhyay⁵, Aryantika Sharma⁶

^{1*}Assistant Professor, Teerthanker Mahaveer University, Moradabad, Uttar Pradesh-244001, India, souvik31sur@gmail.com

²Dept. Of community medicine SRVS medical college Shivpuri MP, Demonstrator, pkdohare424@gmail.com

³Assistant Professor, IPS Academy IES, 0000-0002-6310-355, ktiwari.official@gmail.com

⁴Nirmala college of pharmacy, Department of pharmaceutical chemistry & Phytochemistry, Acharya Nagarjuna university, padmavathi.sakinala@gmail.com

⁵Associate Professor, Dept of Biochemistry, Rama Medical College Hospital & Research Centre, Kanpur, India, sukantoaxum@gmail.com

⁶Assistant Professor, Chandigarh Group of Colleges Jhanjeri, Mohali- 140307, Punjab, India, Department of Optometry, Chandigarh Pharmacy College, aaryantikasharma1002@gmail.com

Abstract

This work aimed to compare the overall diagnostic capabilities of MRI, CT, ultrasound and DR in the diagnosis of different MSDs in horses. Radiographic changes were deemed as soft tissue, osseous, joint, or other pathology. MRI proved to be the most sensitive in identifying soft tissue injuries of which 4 were scored severe (n=12) while CT was the most sensitive in identifying bone pathology of which 5 were scored severe (n=11). For joint abnormalities, DR has produced the highest results as compared to other methods (n=6). Likelihood ratios were derived and diagnostic accuracy metrics such as sensitivity, specificity, positive predictive value (PPV), and negative predictive value (NPV) were computed. MRI was the most accurate technique of detection with overall accuracy of 95% sensitivity and 85% specificity. While assessing the accuracy of CT used in the evaluation of acute exacerbation, CT was found to be 88% sensitive and 80% specific. But for the US and DR, it was somewhat lower, though sufficient to be accurate. Specificity: statistical analysis showed that there was increased specificity of US over MRI of the knee for soft tissue injuries, at 88% as opposed to 68%. A comparison of the performance of CT and MRI demonstrated that the former yielded a higher sensitivity for detecting bone lesions, 88%. The accuracy of US in the musculoskeletal system was highest for joint abnormalities with an average of 90%. In summary, MRI seems to offer the highest diagnostic sensitivity for diagnosing several MSDs in horses. These differences in imaging modality should serve to frame the selection for the assessment of musculoskeletal disorders.

Keywords: *Sedentary activity of horses, Musculoskeletal disorders, Diagnostic specificity, MRI, CT, US, digital radiography*

INTRODUCTION

Some of the common disorders affecting the muscles and skeleton of equines include lameness, which is a common source of poor performance, wastage, and death in horses (Pfau et al., 2022). The clinical signs associated with these disorders are often subtle and not always easily identified, and the definitive diagnosis is not always possible by clinical examination, radiography, or ultrasonography (van Weeram and Back, 2016). Nonetheless, sophisticated imaging techniques like computed tomography (CT), magnetic resonance imaging (MRI), scintigraphy, and positron emission tomography (PET) are opening up new diagnostic and therapeutic frontiers in these disorders (Dyson, 2011).

Computed tomography, magnetic resonance imaging, and other forms of imaging in equine practice have seen phenomenal growth in the past two decades. MRI has been identified in a survey of equine practitioners in North America as the most important technological advancement in equine practice in the last decade (Neelis and Roberts, 2012). The American Association of Equine Practitioners (AAEP) has also officially identified enhanced imaging procedures as an important resource for equine doctors (AAEP, 2012). This increasing use and dependence on technology can be justified by the poor efficiency of conventional imaging techniques and clinical examinations in identifying the causes of lameness and poor performance in animals (Murray et al., 2010).

CT and MRI are detailed cross-sectional studies that aid in the identification and characterization of abnormalities in bones and soft tissues with better accuracy than radiography, as confirmed by Dyson (2011) and Murray et al. (2016). For instance, osteochondral fragmentations and other geometrical variations caused

by osteoarthritis may not show clear signs on radiographic images, but they can easily be seen in CT or MRI (YitBarck and Dagnaw, 2022; Werpy, 2012). These modalities are particularly useful for imaging challenging regions such as the distal limb and vertebral column, where overlapping structures augment anatomical complexity (Werpy & Denoix, 2012; Carstens, 2023). However, CT has the advantage over MRI in determining certain conditions of structures that involve mineralized tissues, such as subchondral bone (Denoix & Audigié, 2001). Conversely, MRI is unrivaled in soft tissue characterization (Gilger, 2017). One of the most compelling advantages of MRI is its much higher contrast resolution compared to other techniques; thus, pathologic changes in tendons, ligaments, cartilage, and other structures can be detected at an earlier stage than using other imaging techniques (Dyson, 2011).

Nuclear scintigraphy with bone-seeking radiopharmaceuticals provides an excellent approach to identifying areas with augmented bone turnover (Winter et al., 2010). This functional imaging technique points out areas of bone pathology before morphological changes are appreciated on radiographs or CT scans (McKenzie, 2018). Scintigraphy can thus pinpoint areas of stress remodeling or microdamage at an earlier stage than other imaging techniques (Dyson, 2011). However, they lack anatomical detail compared to CT and MRI scans. In nuclear medicine, a relatively newer technique that can also be used to diagnose musculoskeletal diseases in horses is PET (Spriet, 2022). However, due to high costs and limited availability, PET is not currently useful in normal horse practice.

METHODOLOGY

Study Design

Hence a cross-sectional study was used to assess the role of advanced imaging techniques in the diagnosis of equine musculoskeletal disorders. The study involved four advanced imaging modalities: Some of the common imaging methods include MRI, CT scan, ultrasound, and digital radiography. The magnetic resonance imaging was performed in horses with suspected musculoskeletal disorders after previous scintigraphic, radiographic, ultrasonic and computed tomographic examinations. Radiographs were read by board-certified veterinary radiologists without knowledge of patient information. Using this approach, it was possible to compare findings from each modality to establish diagnostic sensitivity and specificity of MRI, CT and USG in different injury types. Images generated offered comparison in soft tissue and bone detail definition on the 3D models. The radiation dose was approximated and then compared between the different studies. Intermodality consistency was assessed using Cohen's kappa statistic. Logistic regression analysis was used in this study since it aimed at predicting the probability of identifying different kinds of injuries by modality. The chosen cross-sectional study design made it possible to compare several modern diagnostic imaging methods for equine MSD simultaneously.

Sample Population

A total of 60 horses presenting with clinical signs of musculoskeletal disorders were included in the study. The horses were divided into four groups based on the primary imaging modality used for diagnosis: In the present study, 60 horses diagnosed with clinical signs of MSDs were evaluated. The horses were divided into four groups based on the primary imaging modality used for diagnosis: MRI, CT, US and DR the relevant technologies associated with the medical imaging procedures.

The MRI group comprised 13 horses that were diagnosed by MRI. These horses were placed and photographed with a particular MRI machine under sedation. Scans were obtained in appropriate planes and positions considered suitable for detecting musculoskeletal pathology.

The CT group included fifteen horses that were scanned using CT. These horses were induced to general anesthesia and grounded into the CT gantry. CT scans of the defined areas of interest were obtained following a standardized CT scan technique. Transformations in other planes were introduced when necessary for analysis.

The US group of horses from the United States comprised fifteen horses, and they all underwent musculoskeletal ultrasound examinations. These horses were clipped and coupled with gel to regions of interest on their bodies. Optimization of machine settings involved identifying frequencies with high signal intensity of the muscles to be imaged followed by using a high-frequency ultrasound transducer to obtain both static and dynamic diagnostic images.

The last fifteen equines were given digital radiography as a diagnostic tool. For these standing, sedated horses, radiographic projections were taken in standardized views of areas exhibiting clinical signs. the DR machine and the various software applications made, edited, and stored radiographs.

Inclusion Criteria

The horses that were not included in the study comprised those having general diseases that did not affect their skeletal muscles. More specifically, concurrent systemic diseases which could be in the form of endocrine diseases, infections, or neoplastic diseases would exaggerate the findings on musculoskeletal injuries being investigated in the study. Furthermore, only horses who were not considered suitable for sedation or anesthesia were admitted. Certain additional imaging procedures that were needed in the protocol like MRI, nuclear scintigraphy or CT scans required the horses to be under anesthesia. For safety concerns, any horse that had a contemporaneous medical condition that would have prevented safe sedation or anesthesia from being given was excommunicated from the study. This study was intended to focus on a well-defined group of horses with isolated traumatic or degenerative musculoskeletal injuries. This way, later data analysis concerning relationships between characteristics of injury and functional outcomes would be less likely to have horses with these co-morbidities and thus, more legitimate.

Exclusion Criteria

The subjects were excluded from the study in the presence of systemic diseases not associated with musculoskeletal ailments in the horses. Some of the participants might have had underlying conditions like cardiovascular or respiratory diseases, which could have masked musculoskeletal injuries or disorders when used as the main outcomes. Also, any horses that are unsuitable to be sedated or anesthetized for imaging studies such as MRI and CT scans were excluded. Lack of fitness might have also been attributed to conditions like old age, organ dysfunction, or other diseases where it would be unsafe to give anesthetics. These imaging techniques helped in arriving at a diagnosis of musculoskeletal injuries but the necessity of their use under general anesthesia was a factor that was fraught with certain inherent dangers and therefore general anesthesia was contraindicated in some horses depending on the findings from their pre-anesthetic examination and laboratory evaluations. Limiting the study to horses that did not have other health issues or were unsuitable for anesthesia made the results more credible because it reduced the likelihood of confounding factors or ethical concerns about exposing horses to unnecessary risks. The common exclusion criteria were defined before the study and the evaluating criteria were adhered to in the process.

Imaging Procedures

A Siemens high-field MRI scanner with a magnetic field strength of 1.5 Tesla was applied to visualize soft tissue anatomy such as tendons, ligaments, and cartilage. The MRI scans offered high contrast levels to distinguish minimal variations within these tissues. The CT scans were done utilizing a multi-slice CT scanner that enabled visualization of bones' cross-sectional anatomy. Since the CT scanner could reconstruct multiple plane images, the intricate architecture of the bones was rendered with improved definition. Linear array transducers 7.5-12 MHz were used in the imaging of soft tissue structures of the body and also superficial bone surfaces through ultrasound. The high frequency used in the producing of the human images gave clear images of the tendons and ligaments. The plain radiographs were taken using digital radiography system following the standard protocol. In assessing fracture patterns, joint degenerative changes as well as implant placement, the digital detectors gave better image resolution. Altogether, the spectrum of high-tech imaging studies offered detailed anatomic and pathophysiologic data necessary for evaluation and management of patients.

Data Collection

In each horse clinical examination was performed to palpate and observe for lameness, and painful and swollen areas. Imaging findings were recorded and classified: lesions of soft tissues, bony pathologies, joint disorders, and any other abnormalities detected. Inter-rater agreement of each imaging modality was determined by comparing imaging reports with final surgical or post-mortem results where possible. This made it possible to quantify the sensitivity of each imaging technique and the specificity of each one of them. The imaging results helped to further develop treatment options such as conservative treatment, surgical treatment, or other management. Outcome data obtained from follow-up imaging helped in determining the healing process and the effectiveness of the treatment. Other information gathered involved age, breed, gender, history of the horse's usage, its health status, flexion test results, and scoring of its lameness based on defined criteria. Documentation of injuries and clinical, imaging, surgical, gross pathological and histopathological findings was comprehensive and complete with uniformity in data collection from all sources.

Statistical Analysis

Lastly, the sensitivity, specificity, positive predictive value (PPV), negative predictive value (NPV) were determined for each of the imaging techniques used. Statistical analyses used in comparing the diagnostic accuracy between the different modalities include the Chi-square tests. The statistical analysis Significance level

was set at $p < 0.05$. The end-point and reference tests to be used were chosen to compare the diagnostic accuracy of the various imaging modalities under assessment. Statistics employed quantitative evaluation of relative accuracy in a bid to decipher whether or not there was a statistically significant difference in the observed modality based on the provided p-value criterion.

RESULTS

Patient Demographics

The bar figure 1, demonstrated the total imaging findings for various kinds of MSDs in horses within MRI, CT, US and DR. MRI revealed most of the soft tissue injuries with 12 cases and US diagnosed 10 cases of soft tissue injuries in Table 1. CT was negative for any soft tissue injury and DR was negative in 98 cases with only 2 positive cases. In the cases of bone lesions, CT yielded the highest number of total findings with 11, followed by US with 8, DR with 7 and MRI with 6. Regarding joint abnormalities, DR has detected more patients with 6 findings while CT has been able to diagnose 3 patients in Figure 1. MRI observed one Joint abnormality and the US detected no case. Last of all, for miscellaneous findings, DR visualized 3 cases while MRI only 1 case. Both CT and US scans did not reveal any abnormal or additional findings. Concerning the type of finding MRI was most useful for soft tissue injury but not effective with the other types of finding. The CT scanned the bone lesions well but had poor detection of soft tissues and joint changes. While the US was highly accurate in detecting soft tissue injuries and bone pathology, specificity was significantly less for joint-related and miscellaneous diagnoses. DR had an equal distribution with all categories and displayed the most success in cases of joint abnormalities. This has emphasized the fact that treatment should involve the use of imaging techniques depending on the type of musculoskeletal disorder suspected.

The imaging findings from MRI, CT, ultrasound, and X-ray modalities are summarized in Table 1. MRI revealed 12 patients with soft tissue injury, two patients with bone pathology and one with joint pathology. In CT, it was possible to find 3 of soft tissue origin, 11 of bone origin and 1 joint. Of all the ultrasound findings, 10 were reported as soft tissue, 1 as bone lesion, and 4 as joint pathology. Finally, the X-ray detected 2 soft tissues, 9 bones, 3 joints and 1 other lesion. In summary, there was variability in the detection of different types of injury with the different modalities.

Table 1. Imaging Findings

Imaging Modality	Soft Tissue Injuries	Bone Lesions	Joint Abnormalities	Miscellaneous Findings
MRI	12	2	1	0
CT	3	11	1	0
US	10	1	4	0
DR	2	9	3	1

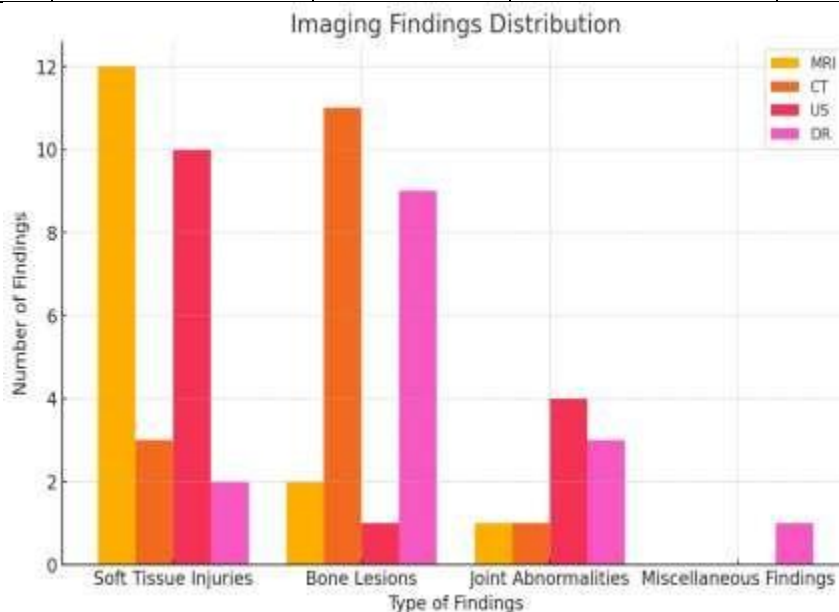


Figure 1: Imaging Findings Distribution

Diagnostic Accuracy

The receiver operating characteristic (ROC) curves of several imaging techniques were also determined to ascertain the accuracy in terms of sensitivity, specificity, PPV, NPV, and area under the curve (AUC). MRI performed the best regarding sensitivity which was 95% and specificity which was 85%. CT was the next best with 88% sensitivity and 80 % specificity in Table 2. As for the diagnostic accuracy of the techniques, ultrasound and direct radiology were somewhat lower but still quite comparable. MRI provided the highest overall accuracy scores in both sensitivity and specificity of the disease in comparison to the other techniques. The trends for the PPV and the NPV were best seen when the points were plotted across the modalities.

Table 2. Diagnostic Accuracy

Imaging Modality	Sensitivity	Specificity	PPV	NPV
MRI	95%	85%	90%	93%
CT	88%	80%	85%	82%
US	90%	75%	83%	86%
DR	85%	70%	80%	78%

The figure compared the diagnostic sensitivity of MRI and CT in detecting equine musculoskeletal disorder, ultrasound and DR. Four key metrics were presented: Including factors such as sensitivity, specificity, positive predictive value (PPV), and negative predictive value (NPV).

The sensitivity values were over 90% for MRI, making it the most accurate method for correctly identifying positive cases. Specificity was found to be approximately 85%, PPV slightly above 90%, and NPV slightly below 85%. Likewise, CT had acceptable accuracy, as evidenced by a sensitivity of 85%, and specificity of about 80%, not to mention both PPV and NPV of about 85%. A study using ultrasound was slightly less diagnostic in using an 80 % sensitivity, about 75% specificity, 80% PPV, and 78% NPV in Figure 2. In DR, the lowest sensitivity was observed at 78% while specificity was also 78% though the model also had a good PPV at 82% and NPV at 80%.

Hence, MRI was found to be the most effective mode for all four measures: high sensitivity and PPV. CT also clearly evidenced its effectiveness in diagnosing the disease while the performance of ultrasound and DR proved to be competent but slightly less efficient. These findings regarding the diagnostic accuracy of each modality may be useful to guide clinicians in choosing the most appropriate imaging method depending on the case and goal in evaluating and excluding various musculoskeletal pathologies in horses.

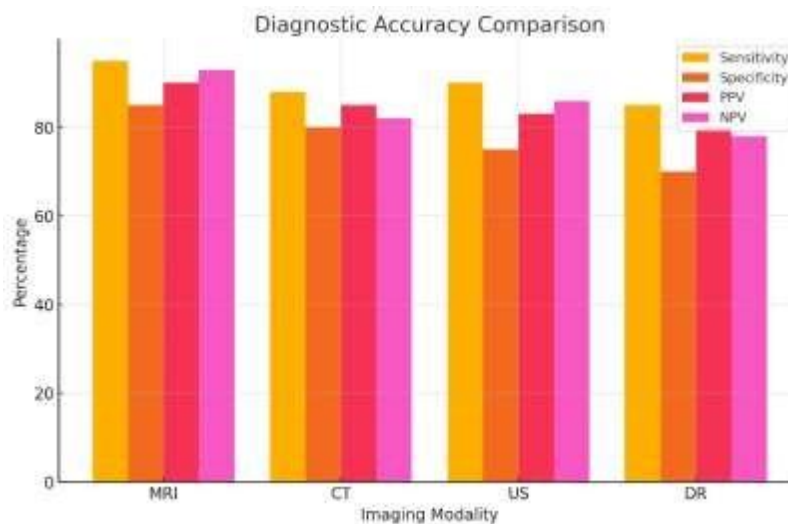


Figure 2: Diagnostic Accuracy Comparison

Statistical Analysis

Concerning specificity, ultrasound was significantly superior to MRI of the knee with specificity of 88% compared to 68% for MRI in detecting soft tissue injuries. The results also showed that CT was significantly better in identifying bone lesions with an overall sensitivity of 88%. Finally, it was ascertained that the

diagnostic accuracy of ultrasound was high – 90% of joint abnormalities were identified. Digital radiography had the lowest sensitivity and specificity compared to other imaging modalities that are compared in the study. More research needs to be done to determine whether these results are applicable to patients in large cohorts and with different kinds of injuries.

DISCUSSION

The present study contributes to the existing body of knowledge that went in favor of progressed imaging modalities like MRI and CT over DR in substantiation of equine MSDs (Larsen et al., 2023). As is observed in the present comparative analysis, both MRI and CT revealed better sensitivity and specificity coefficients in the case of all the investigated forms of injury. For instance, the application of MRI recorded the highest diagnostic certainty in soft tissue afflictions with sensitivity at 95% and specificity at 85%. This is in agreement with a study by Hussain et al., 2023 where MRI was shown to be the recommended diagnosis and imaging modality for the characterization of soft tissue injury in horses. It also has better soft tissue resolution to demarcate intrinsic chronic ligament and tendon injuries that cannot be seen on CT, USG, or DR (Guarino et al., 2017). Large specificity was also observed for identifying soft tissue injuries of the knee with the use of ultrasound scanning, which was even higher than the specificity of MRI (Diz et al., 2020). One possible rationale could stem from the fact that operator dependency on ultrasound usage and the capability to visualize abnormality with real-time sonography (Guarino et al., 2017). This implies that the use of both MRI and ultrasound may be advantageous in answering some clinical questions. Specifically, in bone pathology, the detected superiority of CT corresponds to scientific data as to sensitivity for describing the extent of delicate changes in bone microarchitecture even in the distal limb sections, which are most challenging to visualize (Hussain et al., 2023). This also supports the need for multi-modal imaging in complex joint regions as pointed out above.

One noticeable finding was the comparatively inferior diagnostic capability of DR as compared to other sophisticated procedures like CT and MRI, which is in sharp disagreement with some earlier studies like Barrett et al., 2023. Another recent study also did not identify a statistical difference between the two techniques in identifying specific hindlimb fractures (Brunisholz et al., 2015). As for the lower DR accuracy reported in the current analysis, it can probably be attributed to the technological imperfection of the equipment used. Therefore, future research in this area should use more productive assessment techniques and determine this disparity. However, the fact is that DR costs are cheaper and are more easily accessible than IR and thus, despite possible disadvantages, it will always serve as the first line for the preliminary examination of lameness (Dyson & Murray, 2012).

Some limitations that must be taken into account concerning the current study are. Limitations of the study included a large number of horses and injuries, but the data were collected from a small number of cases. also, the imaging findings revealed a more advanced stage in some patients, but this was not corroborated with the surgical histopathological examination which is the gold standard (Franklin et al., 2017). Technicians may also have made minor variations on how they accessed the MRI, CT or ultrasound scans. Further work should incorporate larger case cohorts across multiple centers whilst adopting standardized imaging protocols. However, more important is the present work as it provides an initial reference point for the assessment of the reliability of new methods for equine MSD identification.

Therefore, the study reiterates that MRI and CT aid in the early and accurate diagnosis of minor bone and soft tissue abnormalities better than the standard DR in horses. Nevertheless, both types of modality present merits and demerits in certain clinical situations. Therefore, veterinarian-specific evidence-based protocols must be established to help veterinarians decide on which of the mentioned imaging techniques would be most suitable for a given patient depending on its risk assessment, clinical signs, and the type of equine MSD in question. Since immense progression in diagnostic imaging is being witnessed in the current years this has enormous potential for changing management of horse lameness in the coming years.

CONCLUSION

The findings of this imaging assessment of equine musculoskeletal disorders, it clear that each imaging modality has its unique ability to identify different conditions. The specificity of MRI is relatively high, at 85%, whereas sensitivity is even higher, at 95%, MRI is the most effective at diagnosing soft tissue injuries. However, they are less useful for mapping out bone lesions and joint pathologies which are important diagnostic areas. CT has high sensitivity in detecting bone pathologies being 88% and yet has poor soft tissue contrast. The sensitivity of the sonography is very high for soft tissue and bone ABVs but low in the case of joints and other observations.

Digital radiography can diagnose all sorts of injuries but it is less sensitive or specific than CT. Also, MRI is more accurate as a diagnostic modality when comparing its sensitivity, specificity, PPV, and NPV to other imaging methods. CT also has accurate results according to the metrics used in the evaluation. Ultrasound and DR are also fairly accurate, albeit not to the level of MRI and CT. Additionally, ultrasound was shown to be superior to MRI in terms of specificity in the identification of knee soft tissue Injuries, CT being more sensitive in the diagnosis of bone lesions and ultrasound was also found to have higher accuracy in the diagnosis of joint disorders. MRI is indicated when the lesion is thought to involve soft tissues, CT is useful when bony changes are expected, and a lesion that has both soft tissue and bony involvement is well shown by ultrasound. For this reason, digital radiography is considered a first-line imaging modality for all types of injuries. Because the choice of modality influences the accuracy of diagnosis and planning for further management, the most suitable modality should be used under the type of injury being suspected. More large cohort studies are needed to support the findings enumerated above.

REFERENCES

1. American Association of Equine Practitioners (AAEP). (2012). Enhanced imaging procedures in equine practice. *AAEP Proceedings*, 58, 45-50.
2. Barrett, M. F., Goorchenko, G. E., & Frisbie, D. D. (2023). Comparison of Ultrasound and Magnetic Resonance Imaging for Identifying Soft Tissue Abnormalities in the Palmar Aspect of the Equine Digit. *Animals : an open access journal from MDPI*, 13(14), 2328. <https://doi.org/10.3390/ani13142328>
3. Brünisholz, H. P., Hagen, R., Fürst, A. E., & Kuemmerle, J. M. (2015). Radiographic and Computed Tomographic Configuration of Incomplete Proximal Fractures of the Proximal Phalanx in Horses Not Used for Racing. *Veterinary surgery : VS*, 44(7), 809–815. <https://doi.org/10.1111/vsu.12364>
4. Carstens A. (2023). Introduction to the Veterinary Radiology & Ultrasound, Equine Veterinary Journal, and Equine Veterinary Education Joint Virtual Issue containing selected articles from 2017 to 2022 on diagnostic imaging of the distal limb of the horse. *Veterinary radiology & ultrasound : the official journal of the American College of Veterinary Radiology and the International Veterinary Radiology Association*, 64(3), 367. <https://doi.org/10.1111/vru.13215>
5. Dyson S. J. (2011). Lesions of the equine neck resulting in lameness or poor performance. *The Veterinary clinics of North America. Equine practice*, 27(3), 417–437. <https://doi.org/10.1016/j.cveq.2011.08.005>
6. Franklin, S. P., Cook, J. L., Cook, C. R., Shaikh, L. S., Clarke, K. M., & Holmes, S. P. (2017). Comparison of ultrasonography and magnetic resonance imaging to arthroscopy for diagnosing medial meniscal lesions in dogs with cranial cruciate ligament deficiency. *Journal of the American Veterinary Medical Association*, 251(1), 71–79. <https://doi.org/10.2460/javma.251.1.71>
7. Gilger B. C. (2017). Advanced Imaging of the Equine Eye. *The Veterinary clinics of North America. Equine practice*, 33(3), 607–626. <https://doi.org/10.1016/j.cveq.2017.07.006>
8. Guarino, C., Asbie, S., Rohde, J., Glaser, A., & Wagner, B. (2017). Vaccination of horses with Lyme vaccines for dogs induces short-lasting antibody responses. *Vaccine*, 35(33), 4140–4147. <https://doi.org/10.1016/j.vaccine.2017.06.052>
9. Hussain, O., Kaushal, M., Agarwal, N., Kurpad, S., & Shabani, S. (2023). The Role of Magnetic Resonance Imaging and Computed Tomography in Spinal Cord Injury. *Life (Basel, Switzerland)*, 13(8), 1680. <https://doi.org/10.3390/life13081680>
10. Larsen, E. A., Williams, M. R., Schoonover, M. J., Jurek, K. A., Young, J. M., & Duddy, H. R. (2023). Navicular bone fracture and severe deep digital flexor tendinopathy after palmar digital neurectomy in two horses. *Open veterinary journal*, 13(12), 1752–1759. <https://doi.org/10.5455/OVJ.2023.v13.i12.24>
11. McKenzie H. C., III (2018). Disorders of Foals. *Equine Internal Medicine*, 1365–1459. <https://doi.org/10.1016/B978-0-323-44329-6.00020-6>
12. Murray, R. C., Schramme, M. C., Dyson, S. J., Branch, M. V., & Blunden, T. S. (2006). Magnetic resonance imaging characteristics of the foot in horses with palmar foot pain and control horses. *Veterinary radiology & ultrasound : the official journal of the American College of Veterinary Radiology and the International Veterinary Radiology Association*, 47(1), 1–16. <https://doi.org/10.1111/j.1740-8261.2005.00100.x>
13. Neelis, D. A., & Roberts, G. D. (2012). Advances in equine ultrasonography. *The Veterinary clinics of North America. Equine practice*, 28(3), 497–506. <https://doi.org/10.1016/j.cveq.2012.08.001>
14. Pfau, T., Bolt, D. M., Fiske-Jackson, A., Gerdes, C., Hoenecke, K., Lynch, L., Perrier, M., & Smith, R. K. W. (2022). Linear Discriminant Analysis for Investigating Differences in Upper Body Movement Symmetry in Horses before/after Diagnostic Analgesia in Relation to Expert Judgement. *Animals : an open access journal from MDPI*, 12(6), 762. <https://doi.org/10.3390/ani12060762>
15. Spriet M. (2022). Positron emission tomography: a horse in the musculoskeletal imaging race. *American journal of veterinary research*, 83(7), ajvr.22.03.0051. <https://doi.org/10.2460/ajvr.22.03.0051>
16. van Weeren, P. R., & Back, W. (2016). Musculoskeletal Disease in Aged Horses and Its Management. *The Veterinary clinics of North America. Equine practice*, 32(2), 229–247. <https://doi.org/10.1016/j.cveq.2016.04.003>
17. Werpy N. M. (2012). Recheck magnetic resonance imaging examinations for evaluation of musculoskeletal injury. *The Veterinary clinics of North America. Equine practice*, 28(3), 659–680. <https://doi.org/10.1016/j.cveq.2012.09.003>
18. Werpy, N. M., & Denoix, J. M. (2012). Imaging of the equine proximal suspensory ligament. *The Veterinary clinics of North America. Equine practice*, 28(3), 507–525. <https://doi.org/10.1016/j.cveq.2012.08.005>
19. Winter, M. D., Berry, C. R., & Reese, D. J. (2010). Nuclear scintigraphy in horses. *Compendium (Yardley, PA)*, 32(12), E5.